

UNIVERSIDADE ESTADUAL DE CAMPINAS
SISTEMA DE BIBLIOTECAS DA UNICAMP
REPOSITÓRIO DA PRODUÇÃO CIENTÍFICA E INTELECTUAL DA UNICAMP

Versão do arquivo anexado / Version of attached file:

Versão do Editor / Published Version

Mais informações no site da editora / Further information on publisher's website:

https://journals.viamedica.pl/folia_morphologica/article/view/91331

DOI: <https://doi.org/10.5603/fm.a2022.0076>

Direitos autorais / Publisher's copyright statement:

©2023 by Via Medica. All rights reserved.

DIRETORIA DE TRATAMENTO DA INFORMAÇÃO








Cidade Universitária Zeferino Vaz Barão Geraldo

CEP 13083-970 – Campinas SP

Fone: (19) 3521-6493

<http://www.repositorio.unicamp.br>

Morphological study of the anatomical variations of anterior belly of digastric muscle in Brazilian cadavers

D.J. Gross¹ , A.C. Rossi¹ , B.C. Ferreira-Pileggi¹ , L.N.O. Watanabe¹ , P.R. Botacin² , F.B. Prado¹ , A.R. Freire¹ 

¹Department of Biosciences, Anatomy Division, Piracicaba Dental School, University of Campinas, Piracicaba, São Paulo, Brazil

²Basic Sciences Department, Araçatuba Dental School, Paulista State University – UNESP, Araçatuba, São Paulo, Brazil

[Received: 8 August 2022; Accepted: 16 August 2022; Early publication date: 25 August 2022]

Background: Cases of variations in anterior belly of the digastric muscle must be carefully identified to avoid misinterpretations and assist in the correct surgical or aesthetic procedure and help in the teaching of anatomy. The aim of this study was to describe the anatomical variations of anterior belly of digastric muscle in Brazilian cadavers.

Materials and methods: Thirty-one human heads were selected, from adult cadavers (18–80 years, 29 males and 2 females). The morphology of the anterior belly of the digastric muscle was observed, identifying the possible anatomical variations that were characterised and classified according to the amount of muscle bellies, fibre direction and place of origin and insertion. The morphometric measurements were performed using a digital calliper. To analyse the data obtained, photographic documentation, anatomical description and individual morphometric description of each muscle belly were performed. The incidence of anatomical variation was obtained in percentage (%).

Results: The anatomical variation of the anterior belly of the digastric muscle was present in 6 cadavers (19.31%; 1 female and 5 male). All anatomical variations presented an accessory belly to the anterior belly. However, these accessory bellies were configured differently in the location, direction of muscle fibres and in their dimensions (length and width).

Conclusions: The gross anatomy of the anterior belly of the digastric muscle and their variations is important to assist in surgical procedures, pathological or diagnostic function. In addition, asymmetrical variations in the submental region must be carefully identified to avoid misinterpretations. (Folia Morphol 2023; 82, 3: 677–682)

Key words: anatomy, digastric muscle, anatomical variations, morphology

Address for correspondence: Prof. A.R. Freire, PhD, Researcher, Department of Biosciences, Anatomy Division, Piracicaba Dental School, University of Campinas, Piracicaba, São Paulo, Brazil, Av. Limeira, 901-Areão, Piracicaba – SP, Brazil 13.414-903, tel: +55 19 21065721, e-mail: alerfreire@gmail.com

This article is available in open access under Creative Common Attribution-Non-Commercial-No Derivatives 4.0 International (CC BY-NC-ND 4.0) license, allowing to download articles and share them with others as long as they credit the authors and the publisher, but without permission to change them in any way or use them commercially.

INTRODUCTION

The digastric muscle (DM) is in the submental region and is a muscle that has two bellies, called the anterior belly and the posterior belly, separated by an intermediate tendon, which forms an anchorage in the hyoid bone. Its origin is characterised by the attachment of the posterior belly to the mastoid notch, at the base of the skull, and its insertion is in the digastric fossa, at the base of the mandible in the chin region. Because they have different embryological origins, DM bellies have different innervation and vascularization, and the anterior belly is innervated by the mylohyoid nerve, a branch of the mandibular nerve. The submental artery and vein, branches of the facial artery and vein, are responsible for its vascularisation [2]. The anterior belly lies superficial to the mylohyoid muscle [6] and its function is to elevate the hyoid bone when the infrahyoid muscles are relaxed and to lower the mandible when the hyoid bone is fixed [13].

The DM shows great variability in size, shape, and number. These variations mainly involve the anterior belly of the muscle and the number of anterior bellies or the presence of accessory bundles originating from a common tendon or the intermediate tendon [4, 9]. The anterior belly variations can be unilateral or bilateral and more rarely being symmetrical, extending to the mandible or the mylohyoid muscle or even crossing the midline to the opposite mylohyoid or the opposite digastric fossa [3].

Digastric muscle variability is of paramount importance during mobilisation of the platysma myocutaneous flap in reconstructive procedures [15]. In-depth knowledge of the typical and variable anatomy of the anterior bellies is of paramount importance due to muscle use after facial nerve paralysis and submental artery flap procedures [16]. In addition, the anterior belly is used as a reference point when identifying the lingual nerve or submandibular gland duct [12].

The submental and submandibular areas are very well vascularised, and knowledge of their muscle abnormalities is essential when a myocutaneous flap is mobilised in reconstructive plastic surgery. Vascular variations can coexist and, to maintain and increase the viability of the flap, the branching pattern of the vessels must be well preserved intraoperatively [10]. Thus, cases of variations in this region must be carefully identified to avoid misinterpretations and assist in the correct surgical or aesthetic procedure and help in the teaching of anatomy.

The aim of this study was to describe the anatomical variations of anterior belly of DM in Brazilian cadavers.

MATERIALS AND METHODS

Ethics approval

The research was analysed and approved by the Committee of Research Ethics of the University of Campinas (Protocol number CEP-FOP-UNICAMP-CAAE 59065622.6.0000.5418).

Sample

Thirty-one human heads belonging to the Laboratory of Anatomy of the Piracicaba Dental School from University of Campinas (FOP-UNICAMP) were selected for the study. The heads were from adult cadavers, selected at random, ranging in age from 18 to 80 years and of both sexes (29 males and 2 females).

The inclusion criteria were as follows: cadaveric specimens from adult individuals with preserved anatomical structures in the submental region, especially the suprahyoid muscles, among which the DM is included. The exclusion criteria were that cadaveric specimens that do not show the preservation of the suprahyoid muscles in the submental region, or that present any pathology that have the presence of a foreign body in the submental region, interfering with the anatomy of the suprahyoid muscles, were excluded.

Calibration

Initially, an anatomical study of the submental region was performed to identify the anatomy of the suprahyoid muscles and adjacent anatomical structures. After this study, the examiner identified the anterior belly of the DM and calibrated the measurements to be performed using a digital calliper (Mituyo®).

Evaluation of the morphology and the morphometry of the anterior belly of the DM

The morphology of the anterior belly of the DM was observed, identifying the possible anatomical variations that were characterised and classified according to the amount of muscle bellies, fibre direction and place of origin and insertion.

The morphometric measurements were performed using a digital calliper (Mituyo®), in which the measurements of the width (mm) and length (mm) of the anterior belly were obtained to add to the morphological descriptions.

Data analysis

To analyse the data obtained, photographic documentation, anatomical description and individual morphometric description of each muscle belly were performed. The incidence of anatomical variation was obtained in percentage (%).

RESULTS

Of the 31 cadavers evaluated, the anatomical variation of the anterior belly of the DM was present in 6 (19.31%; 1 female and 5 male). All anatomical variations presented an accessory belly to the anterior belly of the DM. However, these accessory bellies were configured differently in the location, direction of muscle fibres and in their dimensions (length and width). Anatomical variations are described below. The occurrence of each type can be seen in Figure 1.

Figure 1A and B show anatomical variation of the anterior belly of the DM with the appearance of a unilateral accessory minor belly, in which its muscle fibres originate from the intermediate tendon of the DM and are obliquely directed to insert into the mylohyoid muscle raphe together with mylohyoid muscle fibres. In the total of variations found, 3 heads presented this configuration. In the heads that were found in this configuration, the accessory belly (1a) on the left side (Fig. 1A) had a length equal to 26.36 mm and a width equal to 6 mm. As for the main bellies, the DM anterior belly on the right side had a length of 52.62 mm and a width of 16.22 mm. And the DM anterior belly on the left side had a length equal to 54.27 mm and width equal to 20.94 mm. In Figure 1B, the accessory belly (1a) was located on the right side, with a length equal to 26.70 mm and width equal to 12.47 mm. As for the main bellies, the DM anterior belly on the right side had a length equal to 43.43 mm and a width equal to 11.42 mm. And the DM anterior belly on the left side had a length equal to 33.35 mm and width equal to 15.08 mm.

In Figure 1C, a more complex configuration can be seen, in which the variation occurred bilaterally. The accessory bellies in this configuration originate in the intermediate tendon of the DM and their fibres are directed obliquely across the midsagittal plane until they reach their point of insertion at the base of the mandible on the opposite side in an extension of the digastric fossa. Both accessory bellies are superficial in relation to the mylohyoid muscle. The accessory belly 1a has a length equal to 48.16 mm and a width

equal to 12.54 mm. And the accessory belly 1b has a length equal to 39.16 mm and a width equal to 8.63 mm. As for the main bellies, the DM anterior belly on the right side had a length equal to 40.23 mm and a width equal to 14.26 mm. And the DM anterior belly on the left side had a length equal to 41.16 mm and width equal to 16.11 mm.

In Figure 1D, the variation was presented with the presence of accessory bellies on the right and left sides. Muscle fibres originate from the intermediate tendon of the DM and insert into the extension of the digastric fossa ipsilaterally. However, a small number of fibres can be observed originating from the intermediate tendon on the opposite side, crossing the midline in a similar way to that found in item C of Figure 1. The accessory bellies are found superficially to the mylohyoid muscle. The accessory belly 1a is 26.53 mm long and 6.92 mm wide. And the accessory belly 1b has a length equal to 23.49 mm and a width equal to 4.99 mm. As for the main bellies, the DM anterior belly on the right side had a length equal to 30.17 mm and a width equal to 11.58 mm. And the DM anterior belly on the left side had a length equal to 35.68 mm and a width equal to 8.96 mm.

Considering the variations found, the configuration found in item E of Figure 1 was the most complex. In this situation, the variation appeared bilaterally, with different accessory bellies on each side. In addition, the main anterior belly on the left side also showed an anatomical variation.

On the left side, the main anterior belly originates from the intermediate tendon, but its fibres are directed obliquely to insert into the base of the mandible, right in the midsagittal plane. In addition, part of its fibres has insertion in the mylohyoid muscle raphe. The accessory belly on the left, at its origin, presents fibres together with the main anterior belly. However, when approaching the midsagittal plane, the group of fibres separates to insert into the mylohyoid muscle raphe. Thus, the accessory belly on the left is located posterior to the main anterior belly. On the right side, the main anterior belly did not show variation as on the left side. The accessory belly presented a different configuration from the other variations that were found. Its fibres originate in the intermediate tendon and are directed anteriorly to insert into the digastric fossa together with the main anterior belly. This accessory belly is located laterally in relation to the main anterior belly and is separated from it by

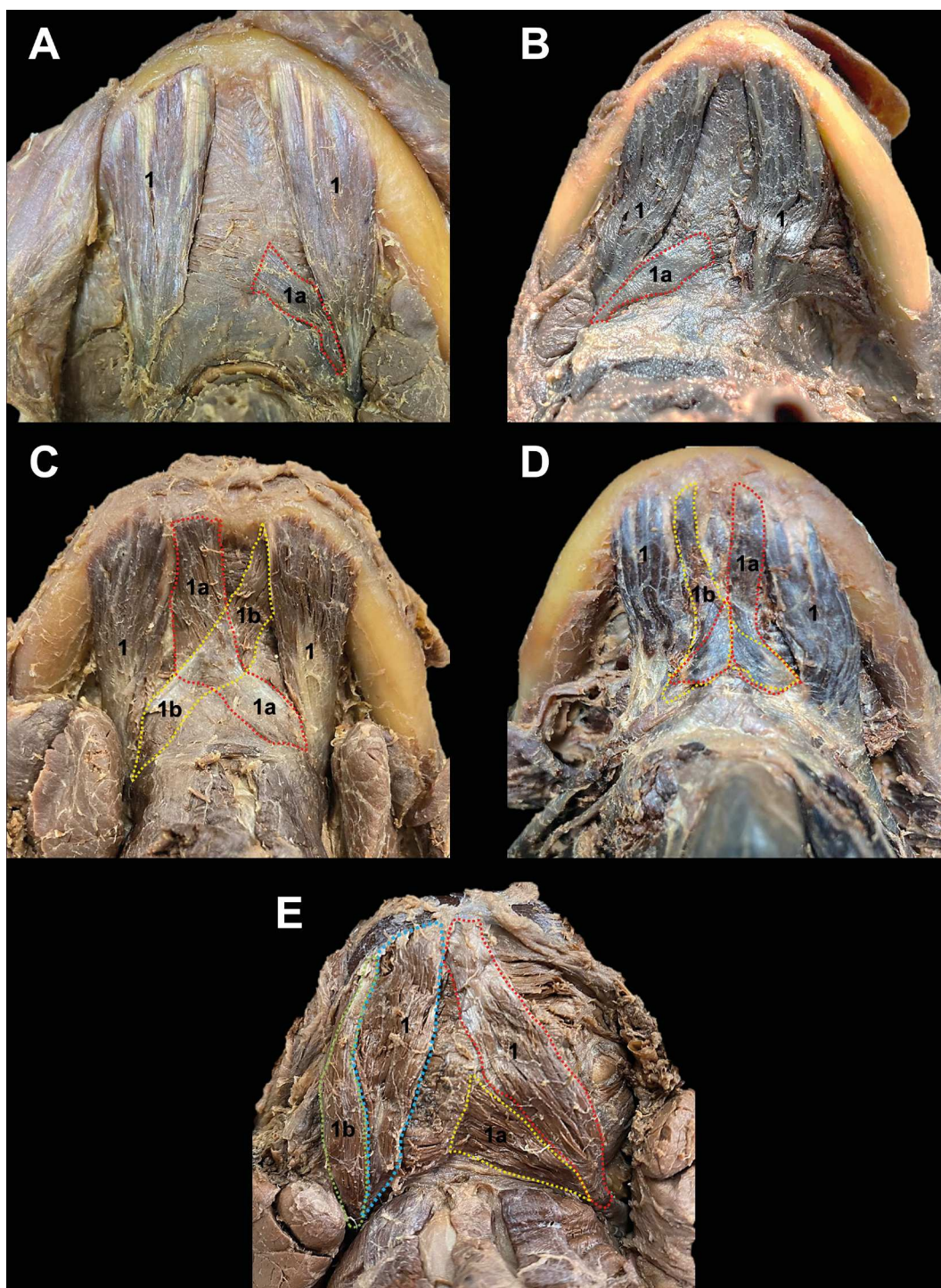


Figure 1. Submental region with emphasis on the location of the anatomical variation of the anterior bellies of digastric muscle. Different colours delimit the belly area; 1 — main anterior belly; lowercase letters — accessory bellies.

a fascia. It is also observed that at its insertion, the accessory belly on this side had a longer tendon in relation to the main anterior belly.

In item E of Figure 1, the anterior belly 1a had a length equal to 24.79 mm and width equal to 12.94 mm. And the anterior belly 1b had a length

equal to 33.03 mm and width equal to 12.94 mm. As for the main bellies, the DM anterior belly on the right side (blue) had a length equal to 34.02 mm and a width equal to 14.13 mm. And the MD anterior belly on the left side (red) had a length equal to 40.94 mm and width equal to 12.20 mm.

DISCUSSION

Digastric muscle variability is of paramount importance during mobilisation of the platysma myocutaneous flap in reconstructive procedures [15]. In-depth knowledge of the typical and variable anatomy of the anterior bellies is of paramount importance due to muscle use after facial nerve paralysis and submental artery flap procedures [16]. In addition, the anterior belly is used as a reference point when identifying the lingual nerve or submandibular gland duct [12].

The knowledge of the anatomical variations of the anterior belly of the DM is also necessary for professionals who perform conservative and surgical treatments in the submental region, as well as in teaching the anatomy of this structure. Therefore, knowing the anatomical variations can facilitate diagnosis and prevent possible complications during surgical procedures [13].

The variations may also be responsible for aesthetic alterations in the submental region. For example, a bulky anterior belly of the digastric muscle can contribute to an unsightly contour of the neck by giving a bulge in the submental area. By removing a good portion of the anterior belly muscle (i.e. making the anterior belly thinner), the bulge in the submental area can be minimised, thus giving the patient a better contour of the neck [5].

Regarding the variations found, ethnicity as the most frequent factor in the occurrence of these variations. Literary data show a higher prevalence of these variations in the Asian population, especially the Japanese. While in the general population a rate of 31.4% was found, in the Asian population the rate was 51.7% for the occurrence of anatomical variation of the DM [1].

Another factor responsible for variations, such as bilateral duplication of the anterior belly, may be the embryological origin, which is explained by a deficiency in the differentiation of the mesoderm of the first pharyngeal arch on both sides or by abnormal migration of the cells of the pharyngeal arch neural crest. In relation to the crossing of muscle fibres in the midline, it may be due to the proximity of the pharyngeal arches [8].

The DM is an important muscle in the neck, which pulls the mandible down to open the mouth and elevates the hyoid bone for stabilisation during swallowing and is also involved in chewing and speaking. In the functional aspect, the changes may affect some DM functions. For example, in crossed anterior bellies,

the difficulty of opening the mouth is suggestive. Probably, the crossing of the bellies makes it difficult for the mandible to be moved downwards.

In the supernumerary bundles, due to their proximity to the anterior belly of the digastric and mylohyoid muscles, additional force is likely to be provided to these muscles during mastication [14]. In the case of the additional belly or unilateral accessory, an imbalance can occur when elevating the hyoid bone or lowering the mandible [11]. These unilateral or bilateral muscle bundles or slips may occur because of a phylogenetic reduction of the DM or an unusual development of ontogenetic material [3].

Notably, knowing the variations found, clinicians and surgeons can make use of and must be very careful in interpreting radiographs and computed tomography scans, as the variations may appear like soft tissue masses, especially in the unilateral type [13].

CONCLUSIONS

The gross anatomy of the anterior belly of the DM and their variations is important to assist in surgical procedures, pathological or diagnostic function. In addition, asymmetrical variations in the submental region must be carefully identified to avoid misinterpretations.

Acknowledgements

The authors sincerely thank those who donated their bodies to science so that anatomical research could be performed. Results from such research can potentially increase mankind's overall knowledge that can then improve patient care. Therefore, these donors and their families deserve our highest gratitude [7].

The authors are grateful to the technician of the Anatomy Laboratory, sr. Cristiano Manoel, for performing the gross anatomic dissections.

Conflict of interest: None declared

REFERENCES

1. Arayapisit T, Vorakulpipat C, Srimaneekarn N, et al. Anatomical variations of the anterior belly of the digastric muscle in Thai cadavers: a cross-sectional study. *J Int Soc Prev Community Dent.* 2022; 12(2): 171–177, doi: [10.4103/jispcd.JISPCD_188_21](https://doi.org/10.4103/jispcd.JISPCD_188_21), indexed in Pubmed: [35462749](https://pubmed.ncbi.nlm.nih.gov/35462749/).
2. Aszmann OC, Ebmer JM, Dellon AL. The anatomic basis for the innervated mylohyoid/digastric flap in facial reanimation. *Plast Reconstr Surg.* 1998; 102(2): 369–372, doi: [10.1097/00006534-199808000-00010](https://doi.org/10.1097/00006534-199808000-00010), indexed in Pubmed: [9703071](https://pubmed.ncbi.nlm.nih.gov/9703071/).

3. Atamaz Pinar Y, Govsa F, Bilge O. The anatomical features and surgical usage of the submental artery. *Surg Radiol Anat.* 2005; 27(3): 201–205, doi: [10.1007/s00276-005-0317-8](https://doi.org/10.1007/s00276-005-0317-8), indexed in Pubmed: [16003485](https://pubmed.ncbi.nlm.nih.gov/16003485/).
4. Celik HH, Aldur MM, Ozdemir B, et al. Abnormal digastric muscle with unilateral quadrification of the anterior belly. *Clin Anat.* 2002; 15(1): 32–34, doi: [10.1002/ca.1088](https://doi.org/10.1002/ca.1088), indexed in Pubmed: [11835541](https://pubmed.ncbi.nlm.nih.gov/11835541/).
5. Connell BF, Shamoun JM. The significance of digastric muscle contouring for rejuvenation of the submental area of the face. *Plast Reconstr Surg.* 1997; 99(6): 1586–1590, indexed in Pubmed: [9145126](https://pubmed.ncbi.nlm.nih.gov/9145126/).
6. Hollinshead WH. The Jaws, Palate and Tongue, In: *Anatomy for Surgeons*. Vol. 1, 3rd print, A Hoeber – Harper Book, New York 1961: 340–400.
7. Iwanaga J, Singh V, Ohtsuka A, et al. Acknowledging the use of human cadaveric tissues in research papers: Recommendations from anatomical journal editors. *Clin Anat.* 2021; 34(1): 2–4, doi: [10.1002/ca.23671](https://doi.org/10.1002/ca.23671), indexed in Pubmed: [32808702](https://pubmed.ncbi.nlm.nih.gov/32808702/).
8. Kim SD, Loukas M. Anatomy and variations of digastric muscle. *Anat Cell Biol.* 2019; 52(1): 1–11, doi: [10.5115/acb.2019.52.1.1](https://doi.org/10.5115/acb.2019.52.1.1), indexed in Pubmed: [30984445](https://pubmed.ncbi.nlm.nih.gov/30984445/).
9. Mangalagiri AS, Razvi MR. Variations in the anterior belly of digastric. *Int J Health Sci (Qassim).* 2009; 3: 257–262.
10. Natsis K, Piagkou M, Lazaridis N, et al. Asymmetry of the accessory anterior digastric muscle bellies: the clinical significance in facial and neck surgery. *Cureus.* 2020; 12(2): e7148, doi: [10.7759/cureus.7148](https://doi.org/10.7759/cureus.7148), indexed in Pubmed: [32257693](https://pubmed.ncbi.nlm.nih.gov/32257693/).
11. Netter FH. Neck. In: Hansen JT, Benninger B, Brueckner JK, Carmichael SW, Granger NA, Tubbs RS (eds.). *Atlas of Human Anatomy*. 5th ed. Elsevier, Philadelphia 2011: 26–34.
12. Norton MR. Bilateral accessory digastric muscles. *Br J Oral Maxillofac Surg.* 1991; 29(3): 167–168, doi: [10.1016/0266-4356\(91\)90030-9](https://doi.org/10.1016/0266-4356(91)90030-9), indexed in Pubmed: [1873284](https://pubmed.ncbi.nlm.nih.gov/1873284/).
13. Reyes G, Contreras C, Ramírez LM, et al. The digastric muscle's anterior accessory belly: case report. *Med Oral Patol Oral Cir Bucal.* 2007; 12(5): E341–E343, indexed in Pubmed: [17767094](https://pubmed.ncbi.nlm.nih.gov/17767094/).
14. Sowman PF, Flavel SC, McShane CL, et al. Asymmetric activation of motor cortex controlling human anterior digastric muscles during speech and target-directed jaw movements. *J Neurophysiol.* 2009; 102(1): 159–166, doi: [10.1152/jn.90894.2008](https://doi.org/10.1152/jn.90894.2008), indexed in Pubmed: [19420123](https://pubmed.ncbi.nlm.nih.gov/19420123/).
15. Turan-Ozdemir S, Oygucu IH, Kafa IM. Bilateral abnormal anterior bellies of digastric muscles. *Anat Sci Int.* 2004; 79(2): 95–97, doi: [10.1111/j.1447-073x.2004.00065.x](https://doi.org/10.1111/j.1447-073x.2004.00065.x), indexed in Pubmed: [15218629](https://pubmed.ncbi.nlm.nih.gov/15218629/).
16. Uzun A, Aluclu A, Kavakli A. Bilateral accessory anterior bellies of the digastric muscle and review of the literature. *Auris Nasus Larynx.* 2001; 28(2): 181–183, doi: [10.1016/s0385-8146\(00\)00100-0](https://doi.org/10.1016/s0385-8146(00)00100-0), indexed in Pubmed: [11240328](https://pubmed.ncbi.nlm.nih.gov/11240328/).