



UNIVERSIDADE ESTADUAL DE CAMPINAS  
SISTEMA DE BIBLIOTECAS DA UNICAMP  
REPOSITÓRIO DA PRODUÇÃO CIENTÍFICA E INTELECTUAL DA UNICAMP



**Versão do arquivo anexado / Version of attached file:**

Versão do Editor / Published Version

**Mais informações no site da editora / Further information on publisher's website:**

[http://www.scielo.br/scielo.php?script=sci\\_arttext&pid=S0103-64402015000400435](http://www.scielo.br/scielo.php?script=sci_arttext&pid=S0103-64402015000400435)

**DOI:** 10.1590/0103-6440201300200

**Direitos autorais / Publisher's copyright statement:**

©2015 by USP/Fundação Odontológica de Ribeirão Preto. All rights reserved.

# cGVHD-Related Caries and Its Shared Features with Other 'Dry-Mouth'-Related Caries

Alan Roger Santos-Silva<sup>1</sup>, Patricia do Socorro Queiroz Feio<sup>1</sup>, Pablo Agustin Vargas<sup>1</sup>, Maria Elvira Pizzigatti Correa<sup>2</sup>, Marcio Ajudarte Lopes<sup>1</sup>

<sup>1</sup>Department of Oral Diagnosis, Semiology Area, Piracicaba Dental School, UNICAMP - Universidade Estadual de Campinas, Piracicaba, SP, Brazil  
<sup>2</sup>BMT Unit, Hematology and Blood Transfusion Center (Hemocentro), UNICAMP - Universidade Estadual de Campinas, Piracicaba, SP, Brazil

Correspondence: Professor Alan Roger Santos-Silva, Avenida Limeira, 901, Caixa Postal 52, 13414-903 Piracicaba, SP, Brasil. Tel: +55-19-2106-5320. e-mail: alanroger@fop.unicamp.br

Several systemic diseases and their medical treatment may predispose the development of aggressive dental caries. Head and neck radiotherapy, chemotherapy, Sjögren's syndrome and long-standing treatment with drugs that induce hyposalivation are some of these conditions. The aim of this article is to describe the clinical features of five patients who developed chronic graft-versus-host-disease (cGVHD) as a complication of allogeneic hematopoietic stem cell transplantation (allo-HSCT) and, in spite of close dental follow-up, subsequently developed rampant caries. In these cases, the restorations showed early failure and the caries still progressed until generalized teeth destruction. The majority of the teeth therefore had to be extracted due to advanced dental caries and rapid clinical progression. Herein the term "cGVHD-related caries" is proposed to describe this under-recognized complication of cancer treatment that may evolve in allo-HSCT recipients that develop cGVHD. This condition is poorly recognized in the literature and may represent the final result of the clustering of oral complications in cGVHD patients, including mucositis, oral pain, hyposalivation, taste loss and oral infections, leading to rampant caries due to impaired oral hygiene and increased intake of highly cariogenic food. Consequently, the knowledge of this oral complication should improve the medical and dental management of cGVHD oral manifestations and improve the quality of life of patients with this post allo-HSCT complication.

**Key Words:** Graft-Versus-Host Disease, hematopoietic stem cell transplantation, dental caries, hyposalivation

## Introduction

Rampant caries (RC) are frequently associated with radiation-related caries in patients treated for head and neck cancer, Sjögren's syndrome and drug-induced hyposalivation (1-5). Interestingly, all these diseases and treatments share a greatly reduced salivary flow and their carious lesions are characterized by rapid onset and progression that usually affect dentition in a generalized way, affecting the surrounding cervical areas of teeth, which lead to teeth crown amputation and cause diffuse teeth destruction and limited overall oral function (2-5).

Graft-versus-host-disease (GVHD) is a syndrome where donor-derived immunocompetent T cells react against human tissues directly or through exuberant inflammatory responses as a consequence of allogeneic hematopoietic stem cell transplantation (allo-HSCT) (6). GVHD can be classified as acute or chronic (cGVHD), which can have an onset of 70 days after HSCT and often continues for many years. GVHD remains the major clinical complication of allo-HSCT limiting survival and inducing major morbidity (6). The most affected target organs of cGVHD are skin, liver and the gastrointestinal tract. However, the oral cavity is also involved in approximately 80% of cases. The most common oral lesions of GVHD are lichenoid-hyperkeratotic mucosa changes, pseudomembranous ulcerations (PU),

mucocoeles and perioral fibrosis (6). Moreover, salivary gland dysfunction is a quite common oral complication in post-allo-HSCT patients (6,7).

Several combined factors have been implicated in the etiology of radiation-related caries. Nevertheless, radiation-induced hyposalivation has been considered the main factor for the development of these caries (8,9). The clinical patterns of dental caries described in patients who have undergone head and neck radiation therapy include diffuse brown discoloration affecting non-cavitated enamel as well as generalized cervical and incisal caries (8,9). Interestingly, in a similar way to these post-radiation subjects, cGVHD patients often experience concurrent oral complications, such as oral pain, mucositis, hyposalivation, taste loss and oral infections. However, little is known concerning the risk for caries development in cGVHD patients. Therefore, the aim of this paper is to describe the clinical features of aggressive dental caries in five patients who developed cGVHD as a complication of allo-HSCT.

## Case Report

### Case 1

A 41-year-old man diagnosed with myelodysplastic syndrome (MDS) was admitted for allo-HSCT and during pretransplantation (pre-HSCT) dental evaluation no

significant oral diseases were observed. The conditioning regimen was a combination of busulfan (BU) and cyclophosphamide (CY). On day 316 (post-HSCT), he was diagnosed with cGVHD affecting the oral mucosa, eyes and skin. Oral GVHD presented as generalized mucosal atrophy, lichenoid hyperkeratotic striae (LHS) on buccal mucosa and generalized erythema; presence of hyposalivation was also observed. The patient presented an overall improvement of the cGVHD-related soft tissue lesions after treatment with cyclosporine A (CsA). After 6 months of dental follow-up, RC was observed. Decay was noticed in the cervical areas of anterior and posterior teeth, which ranged from slight and well-limited brown pigmentation to deep cavitations. Brown discoloration affecting the smooth surfaces of non-cavitated enamel was also evident (Fig. 1A). Oral chlorhexidine rinse (0.12%, alcohol-free) (OCR) was prescribed and the patient used it twice daily after the diagnosis of these caries, which were appropriately managed by composite resin (CR). The carious lesions progressed and tended to lead to tooth crown amputation. In spite of a long-standing (18 years) follow-up based on frequent dental appointments and multiple restorative dental treatments, several teeth were extracted due to the progression of dental caries. The patient is still under careful medical and dental follow-up.

### Case 2

A 47-year-old man diagnosed with MDS was admitted for allo-HSCT and the conditioning regimen of BU/CY was performed. Pre-HSCT oral examination showed loss of several teeth and all carious teeth were restored, scaling and prophylaxis were also performed. On day 306 (post-HSCT), the patient presented cGVHD involving the oral cavity,

eyes, skin and liver. Oral examination showed generalized mucosal atrophy and bilateral LHS on buccal mucosa and tongue. Moreover, the patient reported dysgeusia and hyposalivation was noted. The treatment for cGVHD with CsA resulted in an improvement of the oral and skin lesions as well as liver function. After 4 months, the oral examination showed no soft-tissue lesions, but the presence of cervical and incisal caries decay was evident. OCR was prescribed to be used twice daily and the caries were appropriately restored with CR. However, these restorations showed early failure and the caries still progressed until generalized teeth destruction. Therefore, most of the teeth had to be extracted due to advanced dental caries and rapid clinical progression (Fig. 1B). The patient is under close medical and dental follow-up.

### Case 3

A 33-year-old woman was diagnosed with acute lymphocytic leukemia (ALL) and was subsequently admitted for allo-HSCT. The conditioning regimen based on a combination of BU/VP (etoposide)/CY was performed. During pre-HSCT oral evaluation, no significant oral diseases were observed. On day 101 (post-HSCT) she presented LHS on bilateral buccal mucosa and tongue as well as widespread severe oral PU were observed. Furthermore, dysgeusia and xerostomia were reported by the patient. An improvement of the PU was observed after treatment with CsA but the LHS remained for 2 more months. In addition, on day 200 (post-HSCT), dental caries were identified and an OCR was prescribed twice daily. Widespread cervical and occlusal decay were observed both in anterior and posterior teeth that tended to lead to tooth crown amputation, as shown in Figure 2. All carious lesions were managed appropriately

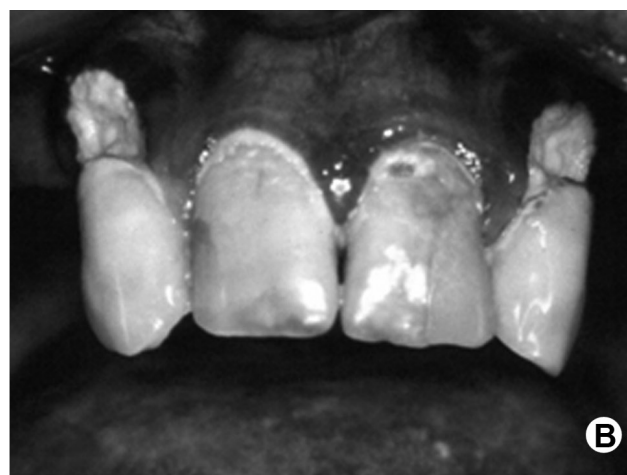
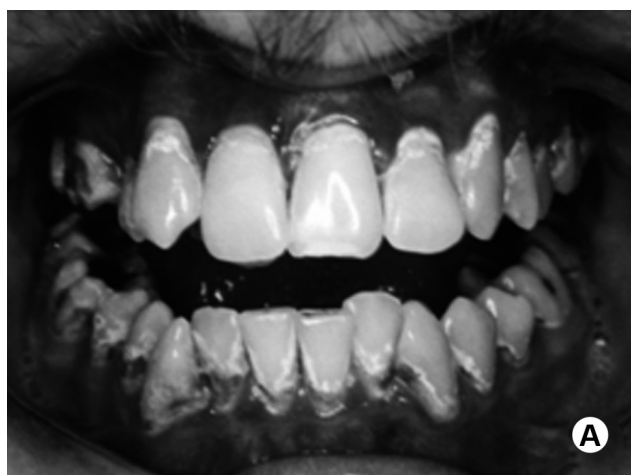
Figure 1. A. Case 1: Incipient clinical patterns of cGVHD-related caries can be seen as generalized superficial carious lesions predominately involving cervical and incisal areas of anterior and posterior teeth. Note that early cervical and incisal carious lesions may develop as well-limited brown pigmentations. B. Case 2: Discrete brown discoloration affecting the smooth surfaces of noncavitated enamel of anterior teeth were observed in association with advanced cervical cGVHD-related caries that tended to result in tooth crown amputation.

with CR. Nevertheless, in less than one year post-HSCT, the progression of caries still continued and endodontic treatment was performed on the majority of the teeth destroyed by caries. After 4 years post-HSCT, the patient is in good general health and under continuous medical and dental care. However, an overall poor oral condition still persists due to the frequent failure of dental restorations and progression of dental caries.

#### Case 4

A 19-year-old man diagnosed with ALL was admitted for allo-HSCT and conditioning regimen of BU/VP/CY was performed. During the first dental appointment he presented only small and limited caries lesions on occlusal surfaces of mandibular molars, which were managed appropriately with CR. On day 358 (post-HSCT), the patient presented cGVHD involving the oral cavity, eyes and liver. The oral lesions were severe gingival atrophy, mucosal erythema and bilateral LHS. In addition, the patient reported xerostomia. cGVHD treatment was performed with CsA and after 2 weeks the patient presented an overall

improvement of the cGVHD-related soft tissue lesions. Six months post-HSCT, dental follow-up showed rampant dental caries affecting cervical surfaces of both anterior and posterior teeth with evident brown pigmentation in these areas. These caries were promptly restored with CR and the patient has been using OCR twice daily since then. In spite of this, in less than one year the caries lesions increased and most of the dental restorations failed due to the rapid progression of the carious lesions, as observed in the panoramic radiograph (Fig. 3). The patient is still under careful medical and dental follow-up.

#### Case 5

A 14-year-old girl was diagnosed with chronic myelogenous leukemia and the patient was subsequently admitted for allo-HSCT and the conditioning regimen based on the combination of BU/CY was administered. A pre-HSCT oral examination showed only the presence of gingivitis, with some localized plaque accumulation in the lingual surface of the mandibular incisors, which was treated with teeth scaling and improvement of oral

hygiene. On day 101 after HSCT she manifested cGVHD that affected the oral cavity, eyes and skin. Dental follow-up showed generalized gingival atrophy, bilateral LHS and PU on buccal mucosa. Furthermore, xerostomia was reported. The treatment for cGVHD was based on the administration of CsA that led to an improvement of the skin lesions and oral PU after 3 weeks. After 4 months, the patient presented diffuse brown discoloration affecting the smooth surfaces of non-cavitated enamel. OCR was prescribed twice daily. After 6 months, these enamel brown discolorations progressed into caries, which were managed with CR. After 18 years of HSCT, the patient is in complete remission of cGVHD. However, she is still under careful medical and dental care and presents recurrent failure of the cervical dental restorations associated with generalized dental destruction due to RC (Fig. 4).

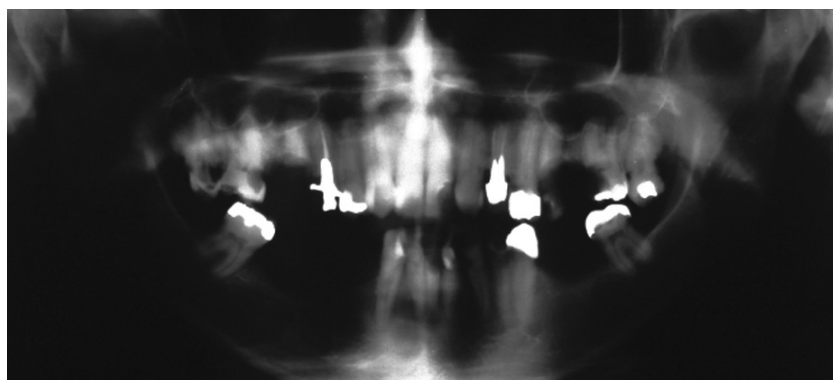


Figure 2. Case 3. Mandible panoramic radiograph exhibiting diffuse dental destruction due to widespread dental caries. Note the tendency of cGVHD-related caries to cause tooth crown amputation.

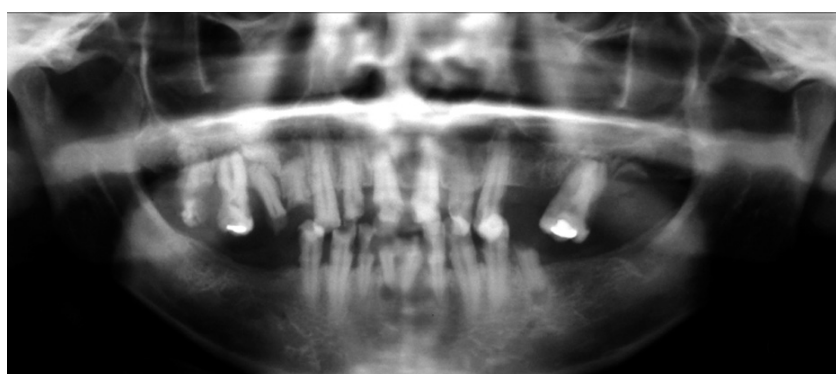


Figure 3. Case 4. Panoramic radiograph showing generalized tooth destruction due to cGVHD-related caries. Note evident cervical and incisal carious lesions.

## Discussion

Allo-HSCT is an essential therapeutic modality applicable to the treatment of a wide range of

diseases, especially blood malignancies. Unfortunately, some patients may develop a series of systemic complications after allo-HSCT, including cGVHD. In this context, salivary gland dysfunction and taste disorders are well-described oral changes in cGVHD patients (6). Since the oral cavity is a common site for manifestations of cGVHD, recognition of these late oral complications may contribute to improving the medical management as well as the overall oral function and eventually a better quality of life in these cancer patients (6,10).

All cases reported in this current series underwent dental screening and treatment before allo-HSCT, thus we were able to demonstrate that they presented a low risk of dental caries at the time of HSCT. Furthermore, the relatively short time required for the development of these RC and the extension of the lesions lead us to believe in an association with cGVHD. Mandibular anterior teeth, which in normal oral conditions are highly resistant to caries, were often affected in the present case series. Cervical areas of anterior and posterior teeth were the most common affected sites. These cervical caries ranged from discrete and well circumscribed brown pigmentations to deep cavitations. Caries affecting the incisal portions of anterior teeth and widespread brown discoloration affecting smooth surfaces of non-cavitated enamel were also evident among all mentioned patients. Thus, cGVHD-related caries were predominately found on teeth surfaces that are rarely affected by dental caries in normal patients. Radiographic examination of patients with cGVHD-related caries confirmed the diffuse and advanced dental destruction. These features of cGVHD-related caries suggest a RC behavior that is very similar to those findings observed

in patients affected by radiation-related caries (2-5).

The effects of allo-HSCT on salivary gland function have been widely described and are mainly attributed to the toxicity of conditioning regimens, including chemotherapy. Additionally, salivary gland diffuse inflammatory infiltration and fibrosis mediated by cGVHD seem to have an important impact on the function of major and minor salivary glands, leading to a reduction of 55-90% of the total salivary flow rate in cGVHD patients (7). Qualitative changes in salivary composition, which include immunological and chemical alterations such as a lower buffering capacity and an increase in cariogenic microorganisms, have been described recently (7,11,12). In our patients, salivary gland impairment was diagnosed based on clinical signs and symptoms, such as absence of the sublingual lake, the presence of a more viscous and mucous residual saliva as well as the lack of saliva on palpation of the parotid duct. Also, all patients reported xerostomia, difficulty in eating, swallowing and dysgeusia. The above-mentioned quantitative salivary changes in cGVHD patients can reduce important functions such as oral anti-infectious activity and protection against mechanical and chemical injuries, leading to lack of resistance during tooth demineralization. The involvement of normally caries-immune and self-cleansing teeth areas found in this case series may strengthen the hypothesis that cGVHD-related caries is mainly caused by changes in salivary flow, resulting in a rapid decalcification of enamel.

Interestingly, only few reports have called attention to the severity of caries in post allo-HSCT patients with cGVHD (10-14). Alborghetti et al. (11) stated that generalized dental tenderness and a higher frequency and severity of cavities were commonly observed during 11 years of dental assistance of post allo-HSCT patients. Another important issue highlighted by this group - and also observed in the current case series - was the precocious infiltration and consequent early failure of dental restorations that were impaired by mouth dryness. Similarly, reduced durability of dental restorations is a major clinical problem in irradiated patients that limits the management of radiation-related caries (15). Recently, Castellarin et al. (10) published a retrospective case-record review with patients who had undergone allo-HSCT and presented cGVHD-associated RC such as the ones described herein. Therefore, comparing the results of the present case series with the above-mentioned scientific body of evidence regarding the increased risk and clinical severity of caries in post allo-HSCT patients with cGVHD, it is possible to confirm a clear relationship between cGVHD and RC.

The current case series aims to call attention to an aggressive form of decay following allo-HSCT, which presents several clinical similarities to radiation-related caries. Also, considering that allo-HSCT patients do not

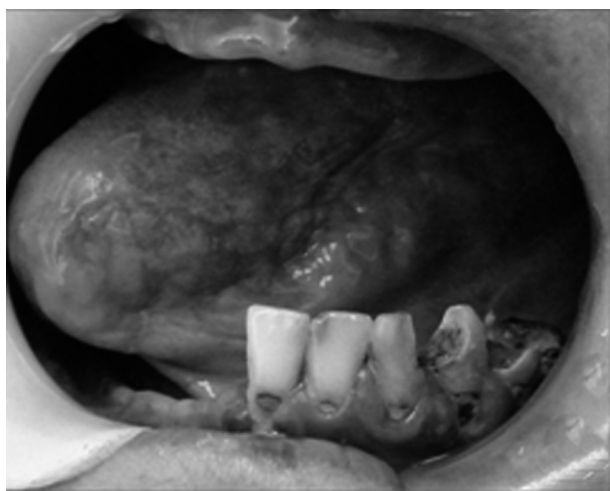


Figure 4. Case 5. Clinical intraoral aspect after 18 years of post-alloHSCT follow-up showing extensive tooth loss, the presence of cervical cavities due to recurrent failure of the cervical dental restorations and a consequent generalized dental destruction due to cGVHD-related caries.



receive radiation to the head and neck region but can develop severe hyposalivation as a consequence of the cGVHD in salivary glands, it is worth considering that these two models of progression of RC have similar etiology and could present shared pathways of progression that might be compared to other hyposalivation-related caries, such as those described in Sjögren's syndrome and in patients under treatment with drugs which predispose to a persistent lack of saliva (2-5).

Recent efforts have confirmed the resemblance between conventional caries and radiation-related caries by showing that the microscopic progression of radiation-related caries presented similar morphological, histological and ultrastructural features as well as the same pattern of demineralization described in conventional caries (5,16,17). Jansma et al. (17) also demonstrated that both natural and induced radiation-related caries showed the same patterns of decay and widespread areas with enamel porosity, crater formation with exposure of subsurface enamel, preferential dissolution of prisms with hollowing out of prism cores, loss of large parts of surface enamel and loss of full enamel coverage exposing the underlying dentin.

Silva et al. (5) recently demonstrated that the patterns of microscopic progression of radiation-related caries follow the same ways of caries in non-irradiated teeth. Similar studies regarding the microscopic features of cGVHD-related caries will be relevant to elucidate the patterns of progression of this under-recognized oral complication of cancer therapy. Such microscopic similar aspects occur because it seems improbable, according to the results of Silva et al. (5) and Faria et al. (26), that the direct effects of radiation in the enamel, dentin and pulp compromise the odontoblastic metabolism, which is essential for reactionary dentin formation (18,19). The above-mentioned studies observed that dentin of irradiated teeth preserved the ability to repair in response to caries progression and the preservation of the pulp micromorphology following *in vivo* head and neck radiation therapy, suggesting that the indirect effects of radiotherapy overcome any eventual direct effects of radiation on tooth structure. It also reinforces the well-established idea that a lack of saliva plays a major role in the aetiology and progression of radiation-related caries (20).

Diffuse and infiltrative brown spots in radiation-related caries characterize areas of demineralization in enamel examined by polarized light microscopy. Clinically, these spots correspond to widespread brown discoloration of the smooth surface of noncavitated enamel (5). Interestingly, diffuse brown spots are considered an important early step during the progression of radiation-related caries whereas a similar clinical pattern was observed in the current patients diagnosed with cGVHD-related caries, but no microscopic

studies have been performed so far in cGVHD-related caries teeth specimens to confirm this observation. On the other hand, it is important to mention that other studies based on *in vitro* radiotherapy and dental tissue found evidence of direct radiogenic destruction to enamel, dentin, enamel-dentin junction, pulp and odontoblasts (18,19,21-24). In spite of the serious psychological, health and economic implications of RC, information is not yet available regarding the microscopic patterns of demineralization and progression of enamel and dentin caries, as well as pulp and dentin viability, in cGVHD-related caries, Sjögren's syndrome patients and in patients taking drugs that are able to induce severe hyposalivation.

In summary, because of the oral secondary effects of the treatments for malignant diseases, such as cGVHD and radiation-induced hyposalivation, lack of saliva should be considered the main shared side effect among these conditions that could explain the similarities between cGVHD-related caries and radiation-related caries. Remarkably, the impact of clustering of oral symptoms from cancer treatment, such as mucositis, dysgeusia, and altered salivary quality and quantity, has been described as a consequence of both head and neck radiotherapy and allo-HSCT (25). Thus, as described for radiation-related caries, they may also work in synergy to promote cGVHD-related caries (8,9). These case series is an attempt to stimulate further research in an under-recognized and severe oral complication that can impair the quality of life of patients with cGVHD. Consequently, it intends to improve the medical and dental management of cGVHD oral complications. Finally, for the first time, the authors would like to suggest the term cGVHD-related caries to designate this oral manifestation in post-HSCT patients.

## Resumo

Diversas doenças sistêmicas e seus tratamentos podem predispor ao desenvolvimento de cáries dentárias agressivas. A radioterapia de cabeça e pescoço, quimioterapia, síndrome de Sjögren e tratamentos prolongados com as drogas que induzem a hipossalivação são algumas destas condições. O objetivo deste artigo é descrever as características clínicas de cinco pacientes que desenvolveram doença do enxerto contra hospedeiro crônica (DECHc) como uma complicação do transplante alogênico de células-tronco hematopoiéticas (aloTCTH) e, apesar do acompanhamento periódico com dentistas, desenvolveram cáries rampantes. Nestes casos relatados, as restaurações mostraram falhas precoces e as cáries continuaram progredindo até a destruição generalizada dos dentes. A maioria dos dentes, portanto, foi extraída devido à cárie avançada e rápida progressão clínica. Neste artigo, o termo "cáries relacionadas à DECHc" é proposto para descrever esta complicação pouco conhecida do tratamento do câncer, que se manifesta em receptores de TCTH que desenvolvem DECHc. Esta condição é pouco reconhecida na literatura e pode representar o resultado final do agrupamento das complicações bucais em pacientes com DECHc, incluindo mucosite, dor oral, hipossalivação, perda de paladar e infecções orais, levando à cárie rampante devido à dificuldade de higiene oral e aumento da ingestão de alimentos altamente cariogênicos. Por consequência, o conhecimento desta complicação oral deve melhorar os tratamentos médico e odontológico das manifestações bucais da DECHc

e melhorar a qualidade de vida dos pacientes com esta complicação após o TCTH.

## Acknowledgements

The authors thank the support of the National Council for the Improvement of Higher Education (research project CAPES/PROEX 758/2012) as well as The Sao Paulo State Research Foundation (research project FAPESP 13/18402-8).

## References

- Hong CH, Napeñas JJ, Hodgson BD, Stokman MA, Mathers-Stauffer V, Elting LS, et al.. A systematic review of dental disease in patients undergoing cancer therapy. *Support Care Cancer* 2010;18:1007-1021.
- Peeters FP, deVries MW, Vissink A. Risks for oral health with the use of antidepressants. *Gen Hosp Psychiat* 1998;20:150-154.
- Mathews SA, Kurien BT, Scofield RH. Oral manifestations of Sjögren's syndrome. *J Dent Res* 2008;87:308-318.
- Gueiros LA, Soares MS, Leão JC. Impact of ageing and drug consumption on oral health. *Gerodontology* 2009;26:297-301.
- Silva AR, Alves FA, Antunes A, Goes MF, Lopes MA. Patterns of demineralization and dentin reactions in radiation-related caries. *Caries Res* 2009;43:43-49.
- Schubert MM, Correa ME. Oral graft-versus-host disease. *Dent Clin N Am* 2008;52:79-109.
- Nagler RM, Nagler A. The molecular basis of salivary gland involvement in graft--vs.--host disease. *J Dent Res* 2004;83:98-103.
- Meurman JH, Grönroos L. Oral and dental health care of oral cancer patients: hyposalivation, caries and infections. *Oral Oncol* 2010;46:464-467.
- Kielbassa AM, Hinkelbein W, Hellwig E, Meyer-Lückel H. Radiation related damage to dentition. *Lancet Oncol* 2006;7:326-335.
- Castellari P, Stevenson K, Biasotto M, Yuan A, Woo SB, Treister NS. Extensive dental caries in patients with oral chronic graft-versus-host disease. *Biol Blood Marrow Transplant* 2012;18:1573-1579.
- Alborghetti MR, Corrêa ME, Adam RL, Metzke K, Coracin FL, de Souza CA, et al.. Late effects of chronic graft-vs-host disease in minor salivary glands. *J Oral Pathol Med* 2005;34:486-493.
- Coracin FL, Pizzigatti Correa ME, Camargo EE, Peterson DE, de Oliveira Santos A, et al.. Major salivary gland damage in allogeneic hematopoietic progenitor cell transplantation assessed by scintigraphic methods. *Bone Marrow Transpl* 2006;37:955-959.
- Curtis JW, Caughman GB. An apparent unusual relationship between rampant caries and the oral mucosal manifestations of chronic graft-versus-host disease. *Oral Surg Oral Med Oral Pathol* 1994;78:267-272.
- Heimdahl A, Johnson G, Danielsson KH, Lönqvist B, Sundelin P, Ringden O. Oral condition of patients with leukemia and severe aplastic anemia. Follow-up 1 year after bone marrow transplantation. *Oral Surg Oral Med Oral Pathol* 1985;60:498-504.
- Silva AR, Alves FA, Berger SB, Giannini M, Goes MF, Lopes MA. Radiation-related caries and early restoration failure in head and neck cancer patients. A polarized light microscopy and scanning electronic microscopy study. *Support Care Cancer* 2010;18:83-87.
- Jansma J, Buskes JA, Vissink A, Mehta DM, Gravenmade EJ. The effect of X-ray irradiation on the demineralization of bovine dental enamel. A constant composition study. *Caries Res* 1988;22:199-203.
- Jansma J, Vissink A, Jongebloed WL, Retief DH, Johannes's-Gravenmade E. Natural and induced radiation caries: A SEM study. *Am J Dent* 1993;6:130-136.
- Al-Nawas B, Grötz KA, Rose E, Duschner H, Kann P, Wagner W. Using ultrasound transmission velocity to analyse the mechanical properties of teeth after *in vitro*, *in situ*, and *in vivo* irradiation. *Clin Oral Invest* 2000;4:168-172.
- Springer IN, Niehoff P, Warnke PH, Böcek G, Kovács G, Suhr M, et al.. Radiation caries - radiogenic destruction of dental collagen. *Oral Oncol* 2005;41:723-728.
- Vissink A, Jansma J, Spijkervet FK, Burlage FR, Coppes RP. Oral sequelae of head and neck radiotherapy. *Crit Rev Oral Biol Med* 2003;14:199-212.
- Bekes K, Francke U, Schaller HG, Kuhnt T, Gerlach R, Vordermark D, et al.. The influence of different irradiation doses and desensitizer application on demineralization of human dentin. *Oral Oncol* 2009;45:e80-e84.
- Grötz KA, Duschner H, Kutzner J, Thelen M, Wagner W. Histotomography studies of direct radiogenic dental enamel changes. *Mund Kiefer Gesichtschir* 1998;2:85-90.
- Kielbassa AM, Beetz I, Schendera A, Hellwig E. Irradiation effects on microhardness of fluoridated and non-fluoridated bovine dentin. *Eur J Oral Sci* 1997;105(5 Pt 1): 444-447.
- Pioch T, Golfels D, Staehle HJ. An experimental study of the stability of irradiated teeth in the region of the dentinoenamel junction. *Endod Dent Traumatol* 1992;8:241-244.
- Santos-Silva AR, Rosa GB, Eduardo CP, Dias RB, Brandão TB. Increased risk for radiation-related caries in cancer patients using topical honey for the prevention of oral mucositis. *Int J Oral Maxillofac Surg* 2011;40:1335-1336.
- Faria KM, Brandão TB, Ribeiro AC, Vasconcellos AF, de Carvalho IT, de Arruda FF, et al.. Micromorphology of the dental pulp is highly preserved in cancer patients who underwent head and neck radiotherapy. *J Endod* 2014;40:1553-1559.

Received April 10, 2015

Accepted June 2, 2015