



UNIVERSIDADE ESTADUAL DE CAMPINAS  
SISTEMA DE BIBLIOTECAS DA UNICAMP  
REPOSITÓRIO DA PRODUÇÃO CIENTÍFICA E INTELLECTUAL DA UNICAMP

**Versão do arquivo anexado / Version of attached file:**

Versão do Editor / Published Version

**Mais informações no site da editora / Further information on publisher's website:**

<https://journals.sagepub.com/doi/10.1177/0161734614546571>

**DOI: 10.1177/0161734614546571**

**Direitos autorais / Publisher's copyright statement:**

©2014 by Sage Publications. All rights reserved.

DIRETORIA DE TRATAMENTO DA INFORMAÇÃO

Cidade Universitária Zeferino Vaz Barão Geraldo

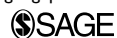CEP 13083-970 – Campinas SP

Fone: (19) 3521-6493

<http://www.repositorio.unicamp.br>

# Two-Dimensional Ultrasound and Ultrasound Elastography Imaging of Trigger Points in Women with Myofascial Pain Syndrome Treated by Acupuncture and Electroacupuncture: A Double-Blinded Randomized Controlled Pilot Study

Ultrasonic Imaging  
2015, Vol. 37(2) 152–167  
© The Author(s) 2014  
Reprints and permissions:  
sagepub.com/journalsPermissions.nav  
DOI: 10.1177/0161734614546571  
ultrasonicimaging.sagepub.com



**Cristina Emöke Erika Müller<sup>1</sup>,  
Maria Fernanda Montans Aranha<sup>1</sup>,  
and Maria Beatriz Duarte Gavião<sup>2</sup>**

## Abstract

Chronic pain has been often associated with myofascial pain syndrome (MPS), which is determined by myofascial trigger points (MTrP). New features have been tested for MTrP diagnosis. The aim of this study was to evaluate two-dimensional ultrasonography (2D US) and ultrasound elastography (UE) images and elastograms of upper trapezius MTrP during electroacupuncture (EA) and acupuncture (AC) treatment. 24 women participated, aged between 20 and 40 years ( $M \pm SD = 27.33 \pm 5.05$ ) with a body mass index ranging from 18.03 to 27.59 kg/m<sup>2</sup> ( $22.59 \pm 3.11$ ), a regular menstrual cycle, at least one active MTrP at both right (RTPz) and left trapezius (LTPz) and local or referred pain for up to six months. Subjects were randomized into EA and AC treatment groups and the control sham AC (SHAM) group. Intensity of pain was assessed by visual analogue scale; MTrP mean area and strain ratio (SR) by 2D US and UE. A significant decrease of intensity in general, RTPz, and LTPz pain was observed in the EA group ( $p = 0.027$ ;  $p < 0.001$ ;  $p = 0.005$ , respectively) and in general pain in the AC group ( $p < 0.001$ ). Decreased MTrP area in RTPz and LTPz were observed in AC ( $p < 0.001$ ) and EA groups (RTPz,  $p = 0.003$ ; LTPz,  $p = 0.005$ ). Post-treatment SR in RTPz and LTPz was lower than pre-treatment in both treatment groups. 2D US and UE effectively characterized MTrP and surrounding tissue, pointing to the possibility of objective confirmation of subjective EA and AC treatment effects.

<sup>1</sup>Department of Morphology, Piracicaba Dental School, University of Campinas, Piracicaba, São Paulo, Brazil

<sup>2</sup>Department of Pediatric Dentistry, Piracicaba Dental School, University of Campinas, Piracicaba, São Paulo, Brazil

## Corresponding Author:

Maria Beatriz Duarte Gavião, Faculdade de Odontologia de Piracicaba/UNICAMP, Av. Limeira 901, Piracicaba, São Paulo 13414-903, Brazil.

Email: mbgaviao@fop.unicamp.br

**Keywords**

ultrasonography, elasticity imaging techniques, myofascial pain syndromes, chronic pain, acupuncture

**Introduction**

Myofascial pain syndrome (MPS) is an important musculoskeletal (MSK) dysfunction<sup>1,2</sup> described as a regional myogenic disorder usually accompanied by local or referred pain, decreased range of motion, weakness, autonomic phenomena, local allodynia, and hyperalgesia in referred pain areas.<sup>3,4</sup> The reported prevalence of MPS in the general population reaches up to 85%.<sup>5</sup> MPS is associated with many pain conditions, including temporomandibular joint disorders, tension-type headache, migraine, spine disorders, and neck and shoulder pain.<sup>6,7</sup> As MPS is often associated with other pathologies, and due to the lack of standardization regarding assessment and diagnosis, the natural history of MPS remains incompletely understood.<sup>8,9</sup>

Travell and Simons first systematically described MPS<sup>10</sup> and reported the presence of hyper-sensitive spots within taut bands of skeletal muscle fibers or fascia, known as myofascial trigger points (MTrP), as the main characteristic of MPS.<sup>5,11</sup> MTrP are classified as active or latent, depending in part on the recognition of pain, either spontaneous or reproduced by palpation, as familiar for the patient. MTrP associated with painful sensations as part of the clinical complaints are considered active MTrP, while those without pain are latent MTrP.<sup>2,5</sup>

Although indicated as the main diagnostic tool for MTrP assessment, manual palpation can show conflicting results in regard to reliability and repeatability as the clinical skill and experience of the examiner can influence outcome.<sup>12,13</sup> Better results are shown in evaluation of the upper trapezius, which is frequently involved with neck pain and chronic tension-type headache due to the high incidence of MTrP.<sup>14,15</sup>

Recent advances in technology have characterized the physical and biochemical nature of the taut bands of skeletal muscle fibers and MTrP by imaging techniques such as ultrasonography (US), magnetic resonance elastography (MRE), sonoelastography (SE), and ultrasound elastography (UE).<sup>12,16-18</sup> These studies showed increased taut band rigidity in MRE images, reduced vibration amplitude of affected tissue by SE, changes in blood vessel systolic and diastolic velocities near MTrP by color Doppler US, and focal hypoechoic areas with heterogeneous echotexture for MTrP by two-dimensional US (2D US). In addition, there are reports of guided MTrP anesthetic injections applied directly at hypoechoic areas assessed by 2D US.<sup>19,20</sup>

UE has the potential to characterize the viscoelastic properties of the tissue, allowing objective MTrP identification due to greater tissue stiffness.<sup>17,21,22</sup> Elasticity variations might be observed as color variance in elastograms.<sup>23</sup> Some equipment allows estimation of the strain ratio (SR) between two regions of interest (ROI), enabling quantification of image findings and providing reference values, such as in breast differential diagnosis.<sup>24</sup> Only few studies thus far have assessed MSK using UE.<sup>25</sup>

Acupuncture (AC) and electroacupuncture (EA), a form of acupuncture in which an electrical current is applied to acupuncture needles,<sup>11</sup> have both been used as alternatives to conventional treatments for MSK pain.<sup>26,27</sup> Melzack et al.<sup>28</sup> and Kao et al.<sup>29</sup> reported a correlation between MTrP and AC points by comparison of their spatial distribution, referred pain, and electrophysiological behavior, supporting the application of these acupuncture techniques in MPS treatment. Although AC and EA have been shown to be effective in chronic pain treatment,<sup>30-32</sup> whether one of these treatments is more effective than the other has not been examined.

Thus, the aim of this study was to evaluate 2D US and UE imaging and elastograms to determine the effectiveness of EA and AC treatment of MTrP in women presenting myofascial pain in the upper trapezius and verify the therapeutic effect on pain intensity.

## Materials and Method

### Design

A double-blinded randomized, controlled, pilot study was conducted between January and August 2013 at the Electromyography and Ultrasonography Laboratory of the Department of Pediatric Dentistry, Piracicaba Dental School, University of Campinas, Piracicaba, Sao Paulo, Brazil, as part of the base research “Evaluation of acupuncture and electroacupuncture in the treatment of myofascial pain of upper trapezius muscle—A double-blinded, randomized, placebo controlled trial” (Sao Paulo Research Foundation—FAPESP 2011/12659-1). The Research Ethical Committee of the Piracicaba Dental School approved the project (Protocol Number 003/2011). The volunteers were asked to read and sign the consent form and were informed about the procedures, discomfort and/or risks, benefits of the research, and the need to attend all sessions. The Brazilian Clinical Trials Registry number is RBR-42kz9z (available at <http://www.ensaiosclinicos.gov.br/rg/RBR-42kz9z/>).

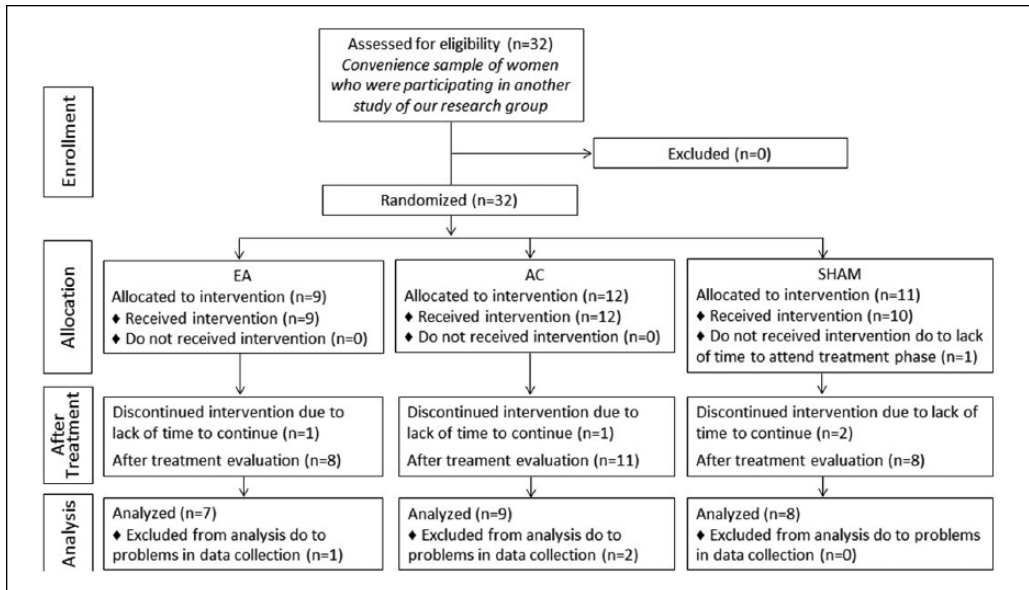
### Study Population

Through local posters, the institutional web page, and personal invitations, responses were solicited from females aged between 18 and 40 years with complaints of pain in the head, neck, and/or upper back for six months or more. These criteria were focused on women of reproductive age to allow menstrual cycle monitoring during the study, as it may influence occurrence and intensity of pain as well as nociception.<sup>33</sup> The following inclusion and exclusion criteria were applied:

*Inclusion criteria:* age range from 18 to 40 years, body mass index (BMI) between 18 and 29.9 kg/m<sup>2</sup> (considering normal range and overweight categories from World Health Organization—WHO Global Database on Body Mass Index; for more details, please see [http://apps.who.int/bmi/index.jsp?introPage=intro\\_3.html](http://apps.who.int/bmi/index.jsp?introPage=intro_3.html)), regular menstrual cycle (using oral contraceptives or not using contraceptives), and one or more active MTTrP in both right and left upper trapezius (RTPz and LTPz, respectively) associated with local and/or referred pain for six months or more.

*Exclusion criteria:* fibromyalgia, cervical radiculopathy, systemic diseases, use of cardiac pacemaker or electronic implants, daily administration of headache and muscular pain medication, physical therapeutic interventions for myofascial pain within the month prior to the study, and pregnancy, all informed by the volunteers. Evident cognitive impairment or communication difficulties and accentuated postural abnormalities were also evaluated by the examiner (C.E.E.M.) at the first meeting.

A convenience sample of 32 women who were participating in the above-cited research was selected. Ages ranged from 20 to 40 years ( $M \pm SD = 27.44 \pm 5.23$ ) and the BMI from 18.03 to 27.59 kg/m<sup>2</sup> ( $22.54 \pm 2.88$ ). The women were randomly distributed into three groups, EA and AC treatment groups, and a control group treated with sham AC (SHAM). The menstrual cycle phase was recorded, and the use of oral contraceptives was indicated as follows: paused oral contraception (POC), continuous oral contraception (COC), and without oral contraception (WOC). Randomization for inclusion in each treatment group was performed using the Microsoft Excel random function. Participants and the examiner were blinded to treatment groups. Five volunteers discontinued the intervention due to lack of time (EA,  $n = 1$ ; AC,  $n = 1$ ; SHAM,  $n = 3$ ). Due to problems in data collection, such as the inability to adequately reproduce the transducer compressions in UE, three volunteers were excluded (EA,  $n = 1$ ; AC,  $n = 2$ ). Thus, the final sample was composed of 24 volunteers ( $M \pm SD$ , age  $27.33 \pm 5.05$  years and BMI  $22.59 \pm 3.11$ ) (Figure 1).



**Figure 1.** Study flow chart. AC = acupuncture; EA = electroacupuncture.

## Procedures

**Myofascial trigger point diagnosis.** The diagnosis of MTrP was performed at the first meeting during a physical examination by a blind examiner (C.E.E.M., a physical therapist with high expertise in MPS diagnosis and management).

During the MTrP evaluation, the volunteer remained seated comfortably in a chair with adjustable height, with feet flat on the floor, knees at 90 degrees and forearms resting on the lower limbs. Palpation protocol was conducted according to the following steps:

1. Palpation over the upper trapezius muscle to identify taut bands and their extension.
2. Gentle compression of painful spots along taut bands to elicit pain and precisely localize tender spots with the aid of verbal information from the subject concerning painful sensations.
3. Sustained compression up to approximately 6 s, depending on individual sensitivity, to elicit pain and confirm referred pain occurrence.

MTrP diagnosis was based on the following five criteria:<sup>1,2,5</sup>

1. Localization of a palpable taut band within skeletal muscle.
2. Hypersensitive tender spot within taut bands.
3. Local twitch response elicited by the snapping palpation of the taut band.
4. Reproduction of the typical referred pain pattern of the MTrP in response to compression.
5. Recognition of pain patterns as familiar.

Furthermore, MTrP were considered active if referred pain, whether spontaneous or evoked by compression, reproduced patient clinical complaint. If the referred pain did not reproduce a familiar pain, MTrP were considered latent.

**Sessions and instrumentation.** Eight treatment sessions were scheduled at the same time of the day over 24 to 26 days, with two sessions each week with a duration of 30 min each.<sup>31</sup> The selected acupuncture points included the gallbladder meridian 20 (GB20), gallbladder meridian 21 (GB21), large intestine four (LI4), liver meridian three (LV3),<sup>34</sup> and up to two Ashi points in each upper trapezius, described as painful points not predicted on meridians and not necessarily coincident with MTrP, although sometimes coinciding.

Stainless steel, individually wrapped, sterilized, disposable needles (0.25 mm diameter × 30 mm length) were used for treatments (Dong-Bang, Korea). For the EA group, treatments were administered with the EL608 electrical stimulation equipment (NKL, Brazil; ANVISA 80191680002), with microprocessed stimulus generation and control, eight isolated outputs through pulse transformers, and yielding asymmetrical biphasic unpolarized waveforms. The equipment was connected to needles inserted in the AC points GB20 and GB21 and in two more Ashi points in each TPz. The frequency was set to alternate between 2Hz (700 μs width, T1 = 5 s) and 100Hz (500 μs width, T2 = 5 s), with a 30 min total treatment. The current intensity was adjusted for the maximum painless stimuli and increased in a gradual manner until a muscle contraction was observed.<sup>32,35</sup> In the SHAM group, needles were inserted superficially 1 cm from the correct AC points<sup>36</sup> for the same treatment time as the other groups. The treatments were performed by a physical therapist (M.F.M.A.) specialized in AC.

**Evaluations.** All evaluations were performed by the same examiner, who had completed one year of training and practice for US and UE techniques (C.E.E.M.), and who was blinded for the treatment type. Pre- and post-treatment evaluations were fixed between the second and fifth menstrual period days according to Greenspan et al.,<sup>33</sup> with an interval ranging from 28 to 30 days, so that the initial and post-treatment evaluations were performed in the same period of the menstrual cycle. Post-treatment evaluation was conducted two to five days after the last session.

**Pain intensity.** Local pain intensity in the RTPz and LTPz, as well as pain in head, neck, and/or upper back (general pain), was quantified using a visual analogue scale (VAS). The VAS consisted of an unanchored horizontal line 10 cm in length, with the left end corresponding to 0 (no pain) and the right end corresponding to 10 (maximum pain). Volunteers were asked to mark their pain intensity on the scale. Afterward, the marked location was measured with a ruler by the blinded examiner.

**Two-dimensional ultrasound and ultrasound elastography.** MTrP in the upper trapezius were evaluated bilaterally through US and UE images at pre- and post-treatment.

The 2D US and UE images and elastograms were acquired using a digital SSA-780A-APLIO MX US (Toshiba Medical Systems Corporation, Japan) equipment with 7 MHz to 18 MHz linear array transducer (38 mm) and Elasto-Q (Toshiba Medical Systems Corporation, Europe) software. For image adjustment, power, intensity, and edge enhancement were established before data collection and remained the same for all pre- and post-treatment examinations. The one-touch Quickscan function was used once per exam, which automatically optimizes 2D US gain level, improving image quality with acoustic precision, while suppressing white noise in echo-weak regions. No manual adjustment of the parameters was performed. Foci placement was also established before data collection and remained the same for all analyses. Next, the volunteer's skin was marked halfway between the seventh cervical vertebra and the tip of the acromion with a pen to guide muscle examination. The blinded examiner performed the exam targeting the transducer at resting LTPz and RTPz, longitudinal to the muscle fascicles, looking for focal hypoechoic areas with heterogeneous echotexture images, which is consistent with presence of MTrP (Figure 2). As all volunteers had active MTrP in both TPz at the point marked on the skin,

or very close to it, the central region of the transducer was always kept over the marked point. The most central MTrP on the pre-treatment images was considered for analysis if more than one MTrP were observed at the same sight. Image J, version 1.45 (National Institutes of Health, U.S.), and the ROI standard measurement tool provided with the software were used to assess MTrP area on 2D US images manually outlined (Figures 3 and 4). Measurements were determined at pre- and post-treatment, and the mean value was used for statistical analysis. The respective images were randomized concerning the treatment groups and observed together to distinguish the anatomic structures and the pattern of muscular tissue providing the confirmation for the examiner if the measurements were performed in the same MTrP. K-PACS software, version 1.6.0 (DICOM Viewing Software, Germany), was used to convert 2D US DICOM format images to JPEG, which could be analyzed with Image J.

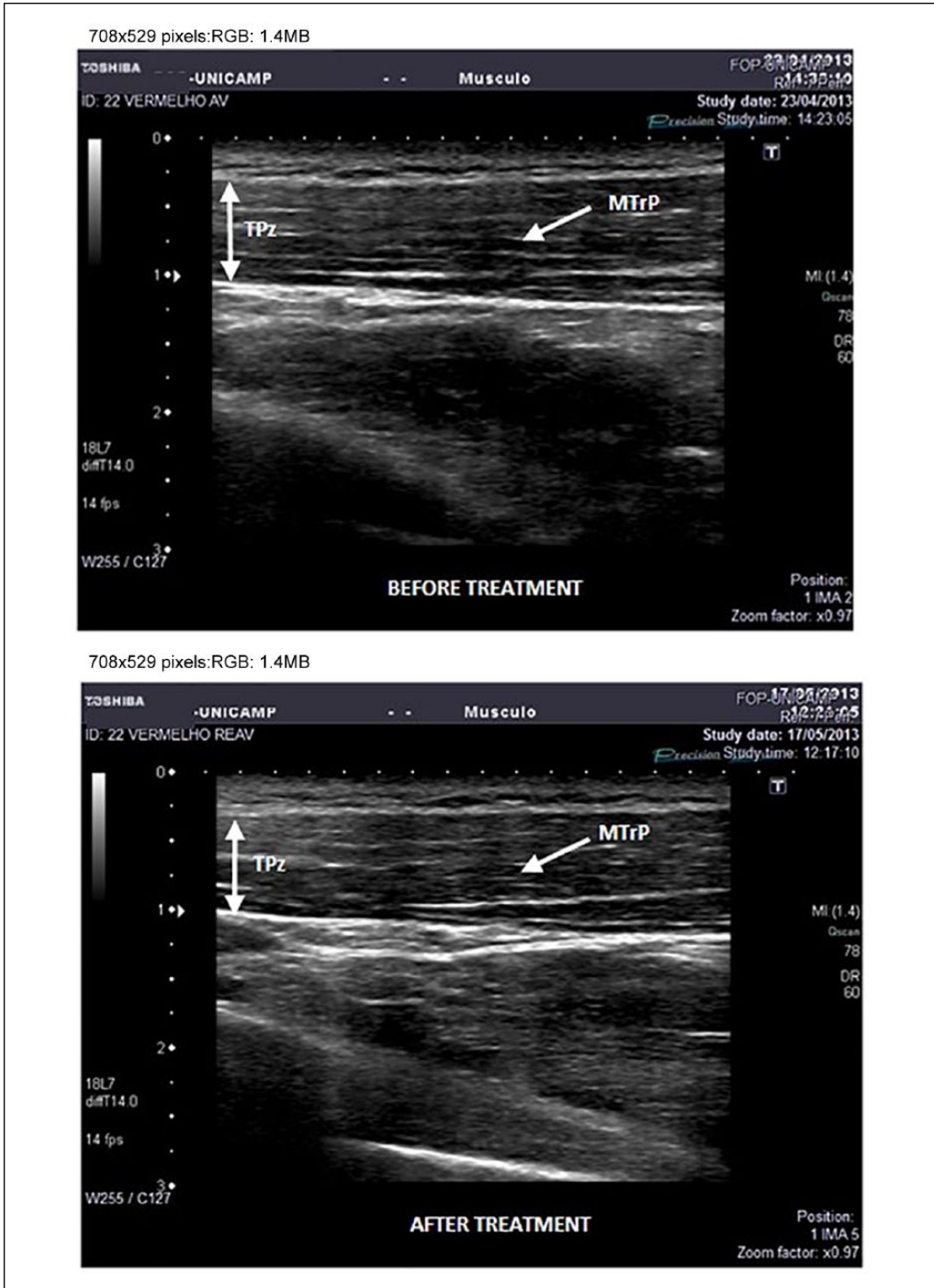
The second step was to perform the UE exam. With the transducer placed over the marked skin, the examiner performed 6 to 10 rhythmically cadenced maneuvers of the transducer over the muscle, following the equipment guidelines for standardization of the technique by tissue compression and decompression sinusoid visualization. The elastograms were then generated using Elasto-Q, which records and enables 2D US and elastogram images for the same sight and provides tools that allow switching between them to verify whether hypoechoic points coincide with the points of increased tissue stiffness. Next, as described in Figure 5, after localization of the best sinusoid compression, two ROI were selected for the SR measurement, considering the mean strain of each ROI. The first point was selected as a reference point in an unaffected and normal region of muscle. The second point indicated tissue with MTrP. This study followed the approach in the previous breast study, in which two ROI are placed at the same tissue depth to minimize possible differences in tissue compression responses due to different depth localization. ROI size was the same for all subjects and for reference and pathological sites. The greatest possible uniformity of color in ROI selection was observed for both reference (green) and pathological (blue) points.

**Statistics.** For statistical analysis of pain intensity (general and localized in both TPz), MTrP mean area and SR, the SigmaPlot version 11.0 (Systat Software, Canada) was used. The assumptions of equality of variances and normal distribution of errors were checked for all variables (Shapiro–Wilk test). To identify homogeneity between the groups in pre- and post-treatment, one-way ANOVA or Kruskal–Wallis test were applied depending on data distribution. Student’s paired *t* test was applied in pre- and post-treatment data, as all data had normal distribution.

## Results

### *Sample Characteristics and Chronic Pain Characterization*

Participants from all three groups ( $n = 24$ ) reported a history of pain of  $6.85 \pm 4.61$  years ( $M \pm SD$ ), with a frequency of  $5.50 \pm 2.06$  times per week. All subjects reported muscular pain in the upper back at both RTPz and LTPz. On closer examination of different regions of the head, 33.3% of the sample ( $n = 8$ ) indicated frontal pain, 54.2% ( $n = 13$ ) temporal, 16.6% ( $n = 4$ ) parietal, and 50.0% ( $n = 12$ ) pain in occiput. A total of 79.2% ( $n = 19$ ) also reported cervicgia, and 33.3% ( $n = 8$ ) reported migraine. Oral contraceptive use was as follows: WOC 25.0% ( $n = 6$ ), POC 54.2% ( $n = 13$ ), and COC 20.8% ( $n = 5$ ). Contraceptive use was randomly distributed among the treatment groups. More information on sample characteristics and group distribution can be seen in Table 1.



**Figure 2.** 2D US images from the same volunteer before and after treatment. Before treatment, normal linear fascicular pattern appeared shapeless, discontinuous, undulated and brighter than after treatment. LTPz = left upper trapezius; MTrP = myofascial trigger points.



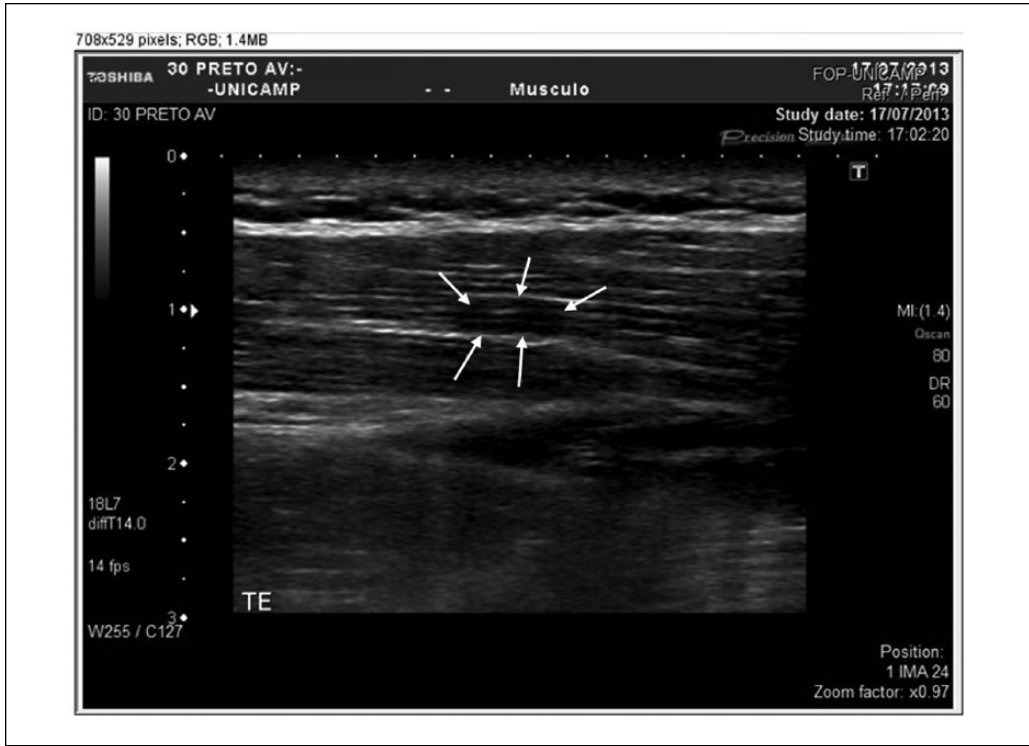


Figure 3. The arrows indicate the hypoechoic region to be outlined. TE = left upper trapezius.

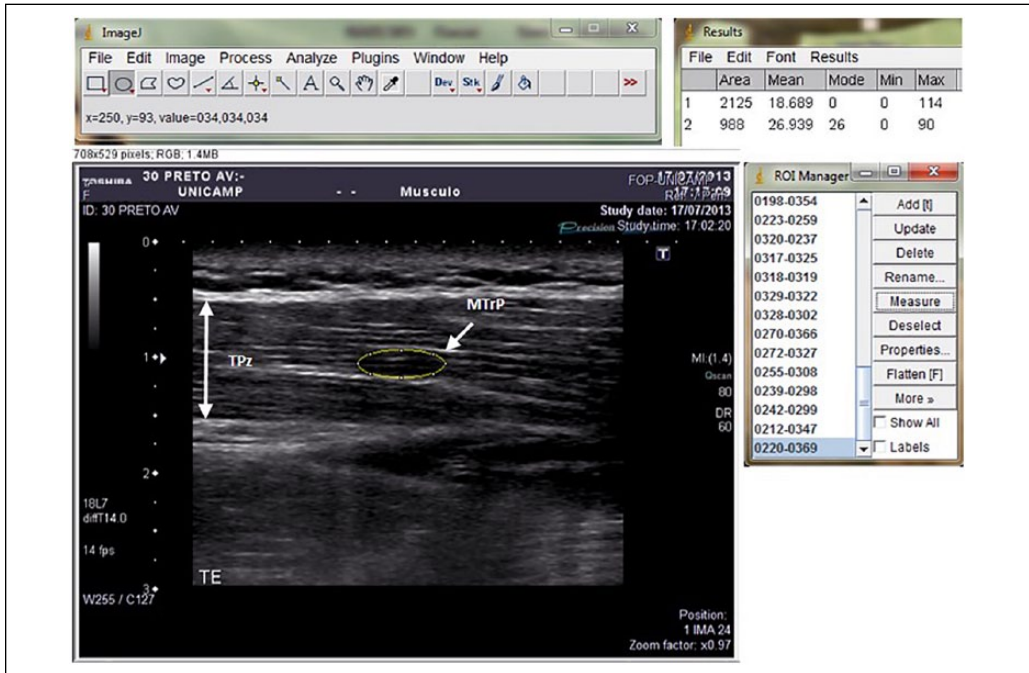
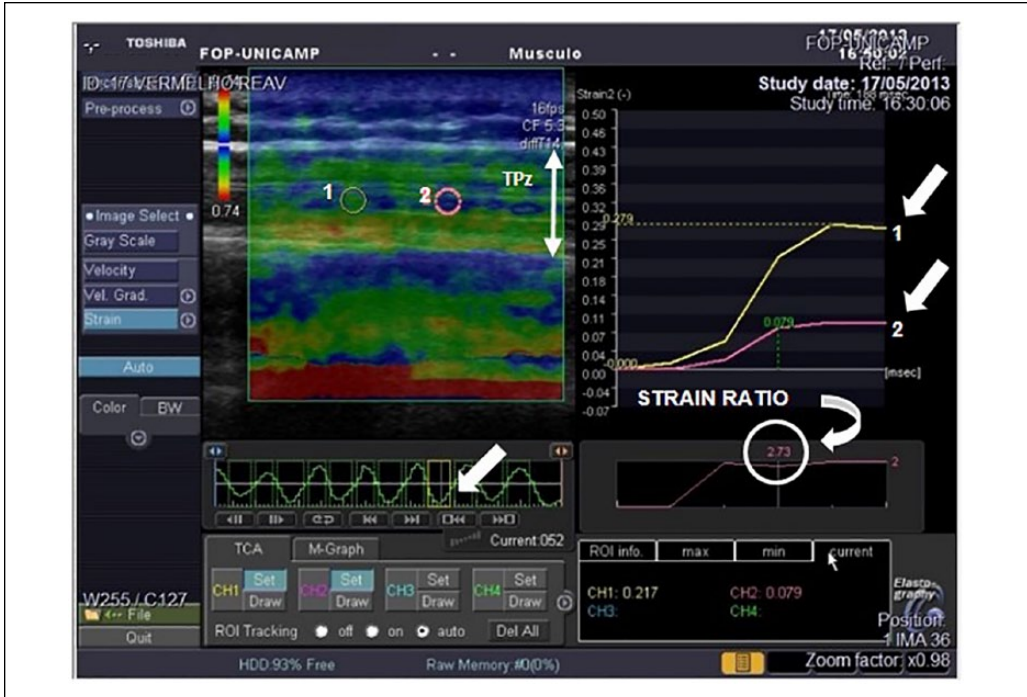


Figure 4. Example of the MTrP area ROI. MTrP = myofascial trigger points; ROI = regions of interest; TPz = trapezius; TE = left upper trapezius.



**Figure 5.** UE of the TPz assessed with Elasto-Q function, which allowed SR measurement. The selection of two ROIs can be observed in the elastogram, in which the color scale indicates elasticity of tissue. Blue indicates lower elasticity, green refers to intermediate elasticity, and red indicates high elasticity and healthy muscle tissue. Immediately below the elastogram, the compression and decompression tissue sinusoid that aided in the standardization of the transducer maneuvers can be observed. In way to SR calculation within collected data, a point at the peak of the best compression sinusoid was selected. ROI 1 and 2 were placed such that ROI 1 corresponded to a reference point in the muscle, presumably without MTrP, and ROI 2 corresponded to a region potentially including MTrP. On the right side of the image, white arrows point to ROI 1 and ROI 2 graphic consisted by tissue strain data for the selected scan time. As predicted, lower values were observed for ROI 2 (MTrP location), consistent with the presumed lower local elasticity from MTrP physiopathology. UE = ultrasound elastography; TPz = trapezius; SR = strain ratio; ROI = regions of interest; MTrP = myofascial trigger points.

### Pain Intensity

Results from the pre- and the post-treatment analyses are shown in Table 2. During pre-treatment, no differences were found among groups regarding general pain ( $p = 0.242$ ) and RTPz and LTPz pain ( $p = 0.876$  and  $p = 0.380$ , respectively, ANOVA). Notably, a decrease of intensity in general, RTPz, and LTPz pain was observed in the EA group and a decrease in general pain in the AC group. No statistically significant results were found in the SHAM group. Moreover, inter-group analysis did not show differences ( $p > 0.05$ ).

### Two-Dimensional Ultrasound

Pre- and post-treatment results are shown in Table 3. MTrP areas were similar among groups before treatment (RTPz,  $p = 0.294$ , Kruskal-Wallis; LTPz,  $p = 0.679$ , ANOVA). After treatment,

**Table 1.** Sample Characteristics, Oral Contraceptive Use Distribution, Chronic Pain Characterization, and Body Pain Locations of the Three Treatment Groups.

Sample Characteristics	EA Group (n = 7)		AC Group (n = 9)		SHAM Group (n = 8)	
	M ± SD		M ± SD		M ± SD	
Age (years)	30.00 ± 4.80		26.33 ± 3.81		26.13 ± 6.13	
BMI (kg/m <sup>2</sup> )	23.19 ± 3.70		21.19 ± 2.80		23.63 ± 2.64	
Oral Contraceptive Use	n	%	n	%	n	%
WOC	2	28.6	2	22.2	2	25.0
POC	4	57.1	5	55.6	4	50.0
COC	1	14.3	2	22.2	2	25.0
Chronic Pain Characterization	M ± SD		M ± SD		M ± SD	
Duration (years)	7.64 ± 5.01		6.11 ± 5.11		7.00 ± 4.14	
Frequency (times/week)	5.00 ± 2.20		6.14 ± 1.57		5.00 ± 2.20	
Body Pain Locations	n	%	n	%	n	%
Head						
Frontal	2	28.6	2	22.2	4	50.0
Temporal	1	14.3	8	88.9	4	50.0
Parietal	0	0	3	33.3	1	12.5
Occipital	2	28.6	5	55.6	5	62.5
Neck	4	57.1	9	100.0	6	75.0
Upper back						
RTPz	7	100.0	9	100.0	8	100.0
LTPz	7	100.0	9	100.0	8	100.0
Migraine	3	42.9	3	33.3	2	25.0

EA = electroacupuncture; AC = acupuncture; BMI = body mass index; WOC = without oral contraception; POC = paused oral contraception; COC = continuous oral contraception; RTPz = right trapezius; LTPz = left trapezius.

significantly lower MTrP area was observed in the EA and AC groups, with nonstatistically significant results in the SHAM group. Inter-group analysis did not show differences ( $p > 0.05$ , ANOVA).

### Ultrasound Elastography

The results for each group are shown in Table 4. There were no differences in SR among groups for RTPz ( $p = 0.230$ ) and LTPz ( $p = 0.089$ ) (Kruskal–Wallis) before treatment. A decrease in SR post treatment was observed in the EA and AC groups, although without statistical significance. The SHAM group results suggest an increase of SR post treatment. Inter-group comparisons did not show any differences ( $p > 0.05$ ).

## Discussion

### Pain Intensity

EA treatment results showed decreased general and local pain intensity, while only general pain was decreased in the AC group. Thus, the analgesic effect of transcutaneous electrical acupoint

**Table 2.** Intra- and Inter-group Comparisons of General Pain Intensity (Head, Neck, and/or Upper Back) and Local RTPz and LTPz Pain Pre- and Post-treatment.

Treatment Group	Pain	VAS Pre-treatment (cm) $M \pm SD$	VAS Post-treatment (cm) $M \pm SD$	$p^a$
EA ( $n = 7$ )	General	6.86 $\pm$ 1.05	2.91 $\pm$ 2.95	0.027
	RTPz	5.16 $\pm$ 1.26	1.50 $\pm$ 1.24	<0.001
	LTPz	4.90 $\pm$ 2.46	1.50 $\pm$ 1.78	0.005
AC ( $n = 9$ )	General	6.03 $\pm$ 1.31	3.14 $\pm$ 1.76	<0.001
	RTPz	5.07 $\pm$ 2.22	3.59 $\pm$ 2.02	0.118
	LTPz	3.02 $\pm$ 2.83	2.61 $\pm$ 2.20	0.603
SHAM ( $n = 8$ )	General	5.60 $\pm$ 1.75	4.78 $\pm$ 2.37	0.296
	RTPz	4.65 $\pm$ 2.43	3.41 $\pm$ 2.52	0.052
	LTPz	4.10 $\pm$ 2.60	3.03 $\pm$ 2.06	0.198

Inter-group comparisons in pre- and post-treatment, ANOVA,  $p > 0.05$ . RTPz = right trapezius; LTPz = left trapezius; VAS = visual analogue scale; EA = electroacupuncture; AC = acupuncture.

<sup>a</sup>Student's paired t test.

**Table 3.** Intra- and Inter-group Comparisons of MTrP Areas Pre- and Post-treatment (Pixels).

Treatment Group	Muscle	Pre-treatment (Pixels) $M \pm SD$	Post-treatment (Pixels) $M \pm SD$	$p^a$
EA ( $n = 7$ )	RTPz	1911.86 $\pm$ 499.21	1252.00 $\pm$ 330.46	0.003
	LTPz	1761.14 $\pm$ 613.09	1324.64 $\pm$ 620.61	0.005
AC ( $n = 9$ )	RTPz	1693.56 $\pm$ 617.52	1070.22 $\pm$ 411.28	<0.001
	LTPz	1553.11 $\pm$ 477.08	1054.61 $\pm$ 400.22	<0.001
SHAM ( $n = 8$ )	RTPz	1520.06 $\pm$ 312.61	1397.75 $\pm$ 253.90	0.117
	LTPz	1549.75 $\pm$ 496.98	1396.25 $\pm$ 362.70	0.093

Inter-group comparisons in pre- and post-treatment, ANOVA,  $p > 0.05$ . MTrP = myofascial trigger points; EA = electroacupuncture; RTPz = right trapezius; LTPz = left trapezius; AC = acupuncture.

<sup>a</sup>Student's paired t test.

**Table 4.** Intra- and Inter-group Comparisons of SR for RTPz and LTPz Pre- and Post-treatment.

Treatment Group	Muscle	Pre-treatment SR	Post-treatment SR	$p^a$	Difference
EA ( $n = 7$ )	RTPz	3.69 $\pm$ 2.80	2.20 $\pm$ 0.96	0.104	1.49 $\pm$ 2.06
	LTPz	2.98 $\pm$ 1.64	2.74 $\pm$ 1.17	0.740	0.23 $\pm$ 1.76
AC ( $n = 9$ )	RTPz	3.14 $\pm$ 1.15	2.46 $\pm$ 0.52	0.216	0.68 $\pm$ 1.53
	LTPz	3.84 $\pm$ 1.51	2.63 $\pm$ 0.95	0.065	1.21 $\pm$ 1.70
SHAM ( $n = 8$ )	RTPz	2.19 $\pm$ 1.01	2.67 $\pm$ 0.76	0.159	-0.48 $\pm$ 0.87
	LTPz	2.39 $\pm$ 1.09	2.56 $\pm$ 1.21	0.678	-0.17 $\pm$ 1.08

Inter-group comparisons in pre- and post-treatment, ANOVA,  $P > 0.05$ . SR = strain ratio; RTPz = right trapezius; LTPz = left trapezius; EA = electroacupuncture; AC = acupuncture.

<sup>a</sup>Student's paired t test.

stimulation, which differs from current EA methodology only by the presence of a transcutaneous electrode instead of the needle, is demonstrated.<sup>37</sup> These results suggest that electrical analgesic stimulation added to the needle stimulation effects at AC points presented better results for local pain than general pain.

Literature comparing EA and AC therapeutic effects on myofascial pain is scarce. Aranha et al.<sup>32</sup> reported a decrease in the intensity of chronic myofascial pain in women treated by EA, which is consistent with the findings of this study. Zheng et al.<sup>30</sup> observed that EA efficacy reduced opioid-like medication, decreased pain intensity, and increased the pressure pain threshold in women with chronic myofascial pain at the upper trapezius after eight EA sessions. As the SHAM group showed nonstatistically significant improvement, higher EA and AC efficiency in the treatment of myofascial pain of the upper trapezius muscle after eight treatment sessions can be suggested.

### *Two-Dimensional Ultrasound*

Through the development of new technologies, US diagnosis of myofascial tissue is now considered the most reliable approach and has been indicated as a method of quantifying grayscale variation findings to confirm results of different treatments. MSK system diseases may appear in 2D US images as grayscale variations due to changes of soft tissue mechanical properties. The subjective image analysis of the present study showed grayscale degree and pattern changes in MTrP areas as focal hypoechoic and heterogeneous echotexture regions, consistent with other studies.<sup>17,20</sup> Conversely, Lewis and Tehan<sup>38</sup> reported unsuccessful MTrP US image diagnosis, which is likely due to technical limitations at the time of study.

The findings showing decreased MTrP areas after treatment of both RTPz and LTPz suggest that EA and AC improved local microvascularization, demonstrating better therapeutic effects on the inflammatory process than the SHAM group, which did not show significant results. The energy crisis theory<sup>5</sup> has been proposed to explain the formation of MTrP as a result of intense contraction of muscle fibers and consequent local hypoxia. In accordance with Shah et al.,<sup>39</sup> 2D US hypoechoic findings correspond to those characteristics, corroborating the energy crisis theory.<sup>5</sup>

From subjective observation of 2D US in this study, brighter lines were observed within muscle fascicles on dysfunctional tissue and appeared to be softer and better organized in healthy tissue. This may be related with increased thickness of myofascial tissue and connective tissue involved in MTrP.

Stecco et al.<sup>40</sup> evaluated the thickness of sternocleidomastoid and scalene muscle fascia and demonstrated a statistically significant decrease in average density of fascia in subjects with chronic neck pain after treatment. Langevin et al.<sup>41</sup> accessed thoracolumbar fascia in individuals with chronic low back pain and demonstrated greater thickness due to the involvement of the myofascial tissue in MPS.

Concerning the characterization of taut bands by 2D US images (which is different from evaluating just the MTrP area), irregular muscle fascicles were observed in affected tissue, in which the normal linear fascicular pattern appeared discontinuous, wavy, or clumped at the taut band.<sup>42</sup> These reported tissue conditions seem to be consistent with the subjective observation of the fascia in this study.

Further studies are necessary to expand proper interpretation of these results.

### *Ultrasound Elastography*

In elastograms, changes in tissue viscoelastic properties are observed by color scale variations. In addition, the SR can be calculated with the aid of specific software available with the US

equipment and has been used in MTrP evaluation in the literature. UE has been well researched and used for breast differential diagnosis, and was even suggested as a benchmark for benign and malignant nodule identification.<sup>24</sup>

Concerning a different elasticity imaging technique associated with US, Langevin et al.<sup>43</sup> accessed thoracolumbar fascia by shear wave elastography in individuals with chronic low back pain and demonstrated reduced shear strain values in the experimental group compared with control healthy subjects. The authors also reported significant correlations between thoracolumbar fascia shear strain and perimuscular connective tissue thickness, which was greater in chronic low back pain subjects.

Although nonstatistically significant values were found for post-treatment SR in the EA and AC groups, the results suggest a possible improvement of tissue conditions, with lower post-treatment SR values in both treatment groups. In comparison, the SHAM group presented the opposite results, showing higher SR post-treatment values, suggesting increased tissue stiffness of MTrP areas compared with its surrounding tissue.

### *Study Limitations*

This study contributes to the development of objective MPS and MTrP evaluation, enabling a better understanding of the natural history and appropriate evaluation and monitoring of patients with chronic myofascial pain. However, several study limitations should be considered. First, this study is exploratory and descriptive, and findings are from a small convenience sample. Thus, further studies with a larger representative number of subjects must be performed.

In addition, some technical difficulties must be addressed. One issue regards the technique of the examiner during the 2D US and UE image capture, during which the amount of pressure, transducer positioning over the muscle, and rhythmically cadenced maneuvers are difficult to control. A second issue relates to the MTrP area assessment, in which images pre- and post-treatment were displayed at the same time for area quantification, allowing the examiner to observe anatomical structures and fascia features to help MTrP localization. Images were displayed simultaneously, as localization would be difficult to confirm in evaluation of independently displayed images. Consequently, as this is a pilot study, the accuracy and reproducibility of the MTrP area and SR must be verified in further studies. Furthermore, to eliminate possible examiner bias, individual evaluation of the images should be considered, as well as to fix a pixel/mm scale in the software.

As taut bands and whole muscle stiffness can improve with treatment, promoting better muscle functioning and general conditions in addition to local benefits, healthy tissue selected at the same depth in elastograms for the SR appraisal may mask results. Thus, according to the recent study by Arijji et al.,<sup>21</sup> reference points outside the target tissue should be considered in further studies, such as subcutaneous adipose tissue as a reference for improvement of muscular stiffness post treatment. However, Fischer et al.<sup>44</sup> noted the selective results from examiner interpretation due to the pressure distribution dependence on the tissue depth as the major bias of compression elastography, which guided the experimental design of this study.

To the best of our knowledge, no previous studies have assessed the dimensions of MTrP and UE SR pre- and post-treatment. As MPS and MTrP diagnoses remain unclear and lack a gold standard,<sup>12,40</sup> further studies are necessary to better define and quantify morphological differences between normal and dysfunctional muscle tissue with MTrP and to confirm the possibility of the application of 2D US and UE imaging technique in MPS and MTrP diagnosis and treatment monitoring. In conclusion, our pilot study supports sample size calculation and new experimental studies to improve methodological tissue evaluation, providing accuracy, sensitivity, and reproducibility of the SR measures and validation of the technique.

## Conclusion

The present study demonstrated the effectiveness of EA and AC in treatment of upper trapezius myofascial pain, and suggested that EA exhibited the most effective results in local analgesia. Improvement of tissue conditions was observed post-treatment for EA and AC, suggesting the possibility of subjective confirmation and quantification of treatment effects using 2D US images. UE showed no significant post-treatment results. However, the trend of decreased post-treatment SR values for EA and AC groups, compared with increased values in the SHAM group, suggests its potential in MTrP and myofascial tissue characterization.

## Acknowledgments

We are grateful to the São Paulo Research Foundation (FAPESP, São Paulo, Brazil) for financial support. We also thank the volunteers.

## Declaration of Conflicting Interests

The author(s) declared no potential conflicts of interest with respect to the research, authorship, and/or publication of this article.

## Funding

The author(s) disclosed receipt of the following financial support for the research, authorship, and/or publication of this article: Cristina Muller received a scholarship from CAPES Foundation, Brazil; Maria Fernanda Montans Aranha received a scholarship from São Paulo Research Foundation, Brazil. The research was supported by the São Paulo Research Foundation (FAPESP, São Paulo, Brazil; Process 2011/12659-1).

## References

1. Skootsky SA, Jaeger B, Oye RK. Prevalence of myofascial pain in general internal medicine practice. *West J Med.* 1989;151:157-60.
2. Gerwin RD, Shannon S, Hong CZ, Hubbard D, Gevirtz R. Interrater reliability in myofascial trigger point examination. *Pain.* 1997;69:65-73.
3. Lavelle ED, Lavelle W, Smith HS. Myofascial trigger points. *Anesthesiol Clin.* 2007;25:841-51.
4. Dommerholt J. Dry needling—peripheral and central considerations. *J Man Manip Ther.* 2011;19:223-7.
5. Simons DG, Travell JG, Simons LS. *Myofascial Pain and Dysfunction: The Trigger Point Manual.* Baltimore, MD: Williams & Wilkins; 1999.
6. Borg-Stein J, Simons DG. Focused review: myofascial pain. *Arch Phys Med Rehabil.* 2002;83:40-9.
7. Fernández-de-las-Peñas C, Galán-del-Río F, Alonso-Blanco C, Jiménez-García R, Arendt-Nielsen L, Svensson P. Referred pain from muscle trigger points in the masticatory and neck-shoulder musculature in women with temporomandibular disorders. *J Pain.* 2010;11:1295-304.
8. Gerber LH, Sikdar S, Armstrong K, Diao G, Heimur J, Kopecky J, et al. A systematic comparison between subjects with no pain and pain associated with active myofascial trigger points. *PM R.* 2013;5:931-8.
9. Fleckenstein J, Zaps D, Rüger LJ, Lehmeier L, Freiberg F, Lang PM, et al. Discrepancy between prevalence and perceived effectiveness of treatment methods in myofascial pain syndrome: results of a cross-sectional, nationwide survey. *BMC Musculoskelet Disord.* 2010;11:32.
10. Travell JG, Simons DG. *Myofascial Pain and Dysfunction: The Trigger Point Manual.* Baltimore, MD, and London: Williams & Wilkins; 1983.
11. Okeson JP. *Bell's Orofacial Pains.* 6th ed. Chicago, IL: Quintessence; 2005.
12. Basford JR, An KN. New techniques for the quantification of fibromyalgia and myofascial pain. *Curr Pain Headache Rep.* 2009;13:376-8.

13. Lucas N, Macaskill P, Irwing L, Moran R, Bogduk N. Reliability of physical examination for diagnosis of myofascial trigger points: a systematic review of the literature. *Clin J Pain*. 2009;25:80-9.
14. Fernández-de-las-Peñas C, Cuadrado ML, Pareja JA. Myofascial trigger points, neck mobility, and forward head posture in episodic tension-type headache. *Headache*. 2007;47:662-72.
15. McEvoy J, Huijbregts PA. Reliability of myofascial trigger point palpation: a systematic review. In: Dommerholt J, Huijbregts P, eds. *Myofascial Trigger Points: Pathophysiology and Evidence-Informed Diagnosis and Management*. Sudbury, MA: Jones & Bartlett Publishers; 2011. pp. 65-88.
16. Chen Q, Bensamoun S, Basford JR, Thompson JM, An K-N. Identification and quantification of myofascial taut bands with magnetic resonance elastography. *Arch Phys Med Rehabil*. 2007;88:1658-61.
17. Sikdar S, Shah JP, Gebreab T, Yen RH, Gilliams E, Danoff J, et al. Novel applications of ultrasound technology to visualize and characterize myofascial trigger points and surrounding soft tissue. *Arch Phys Med Rehabil*. 2009;90:1829-38.
18. Sikdar S, Ortiz R, Gebreab T, Gerber LH, Shah JP. Understanding the vascular environment of myofascial trigger points using ultrasonic imaging and computational modeling. *Conf Proc IEEE Eng Med Biol Soc*. 2010;1:5302-5.
19. Botwin KP, Sharma K, Saliba R, Patel BC. Ultrasound-guided trigger point injections in the cervicothoracic musculature: a new and unreported technique. *Pain Physician*. 2008;11:885-9.
20. Niraj G, Collett BJ, Bone M. Ultrasound-guided trigger point injection: first description of changes visible on ultrasound scanning in the muscle containing the trigger point. *Br J Anaesth*. 2011;107:474-5.
21. Ariji Y, Gotoh A, Hiraiwa Y, Kise Y, Nakayama M, Nishiyama W, et al. Sonographic elastography for evaluation of masseter muscle hardness. *Oral Radiol*. 2013;29:64-9.
22. Turo D, Otto P, Shah JP, Heimur J, Gebreab T, Zaazhoa M, et al. Ultrasonic characterization of the upper trapezius muscle in patients with chronic neck pain. *Ultrason Imaging*. 2013;35:173-87.
23. Gotoh A, Ariji Y, Hasegawa T, Nakayama M, Kise Y, Matsuoka M, et al. Sonographic elastography for assessing changes in masseter muscle elasticity after low-level static contraction. *Oral Radiol*. 2013;29:140-5.
24. Gong X, Wang Y, Xu P. Application of real-time ultrasound elastography for differential diagnosis of breast tumors. *J Ultrasound Med*. 2013;32:2171-6.
25. Correas JM, Drakonakis E, Isidori AM, Hélénon O, Pozza C, Cantisani V, et al. Update on ultrasound elastography: miscellanea. Prostate, testicle, musculo-skeletal. *Eur J Radiol*. 2013;82:1904-12.
26. Li A, Wang Y, Xin J, Lao L, Ren K, Berman BM, et al. Electroacupuncture suppresses hyperalgesia and spinal fos expression by activating the descending inhibitory system. *Brain Res*. 2007;1186:171-9.
27. Taguchi T, Taguchi R. Effect of varying frequency and duration of electroacupuncture stimulation on carrageenan-induced hyperalgesia. *Acupunct Med*. 2007;25:80-6.
28. Melzack R, Stillwell D, Fox E. Trigger point and acupuncture points for pain: correlations and implications. *Pain*. 1977;3:3-23.
29. Kao MJ, Hsieh YL, Kuo FJ, Hong CZ. Electrophysiological assessment of acupuncture points. *Am J Phys Med Rehabil*. 2006;85:443-8.
30. Zheng Z, Guo RJ, Helme RD, Muir A, Da Costa C, Xue CC. The effect of electroacupuncture on opioid-like medication consumption by chronic pain patients: a pilot randomized controlled clinical trial. *Eur J Pain*. 2008; 12:671-6.
31. Sun MY, Hsieh CL, Cheng YY, Hung HC, Li TC, Yen SM, et al. The therapeutic effects of acupuncture on patients with chronic neck myofascial pain syndrome: a single-blind randomized controlled trial. *Am J Chin Med*. 2010;38:849-59.
32. Aranha MF, Alves MC, Bérzin F, Gavião MB. Efficacy of electroacupuncture for myofascial pain in the upper trapezius muscle: a case series. *Rev Bras Fisioter*. 2011;15:371-9.
33. Greenspan JD, Craft RM, LeResche L, Arendt-Nielsen L, Berkley KJ, Fillingim RB, et al. Studying sex and gender differences in pain and analgesia: a consensus report. *Pain*. 2007;132 Suppl. 1:S26-45.
34. Lian YL, Chen CY, Hammes M, Kolster BC. *Pictorial Atlas of Acupuncture: An Illustrated Manual of Acupuncture Points*. Slovenia: h.fullmann; 2005.
35. Zhu XM, Polus B. A controlled trial on acupuncture for chronic neck pain. *Am J Chin Med*. 2002;30:13-28.



36. Xue CC, Dong L, Polus B, English RA, Zheng Z, Da Costa C, et al. Electroacupuncture for tension-type headache on distal acupoints only, a randomized, controlled, crossover trial. *Headache*. 2004;44:333-41.
37. Yuan CS, Attele AS, Dey L, Lynch JP, Guan X. Transcutaneous electrical acupoint stimulation potentiates analgesic effect of morphine. *J Clin Pharmacol*. 2002;42:899-903.
38. Lewis J, Tehan P. A blinded pilot study investigating the use of diagnostic ultrasound for detecting active myofascial trigger points. *Pain*. 1999;79:39-44.
39. Shah JP, Phillips TM, Danoff JV, Gerber LH. An in vitro microanalytical technique for measuring the local biochemical milieu of human skeletal muscle. *J Appl Physiol*. 2005;99:1977-84.
40. Stecco A, Meneghini A, Stern R, Stecco C, Imamura M. Ultrasonography in myofascial neck pain: randomized clinical trial for diagnosis and follow-up. *Surgical & Radiologic Anatomy*. Published electronically August 23, 2013. doi:10.1007/s00276-013-1185-2.
41. Langevin HM, Stevens-Tuttle D, Fox JR, Badger GJ, Bouffard NA, Krag MH, et al. Ultrasound evidence of altered lumbar connective tissue structure in human subjects with chronic low back pain. *BMC Musculoskelet Disord*. 2009;10:151.
42. Shankar H, Reddy S. Two- and three-dimensional ultrasound imaging to facilitate detection and targeting of taut bands in myofascial pain syndrome. *Pain Med*. 2012;13:971-5.
43. Langevin HM, Fox JR, Koptiuch C, Badger GJ, Greenan-Naumann AC, Bouffard NA, et al. Reduced thoracolumbar fascia shear strain in human chronic low back pain. *BMC Musculoskelet Disord*. 2011;12:203.
44. Fischer T, Sack I, Thomas A. Characterization of focal breast lesions by means of elastography. *Rofo*. 2013;185:816-23.