



UNIVERSIDADE ESTADUAL DE CAMPINAS  
SISTEMA DE BIBLIOTECAS DA UNICAMP  
REPOSITÓRIO DA PRODUÇÃO CIENTÍFICA E INTELLECTUAL DA UNICAMP

**Versão do arquivo anexado / Version of attached file:**

Versão do Editor / Published Version

**Mais informações no site da editora / Further information on publisher's website:**

<https://meridian.allenpress.com/angle-orthodontist/article/84/2/274/98365/Influence-of-cone-beam-computed-tomography-image>

DOI: 10.2319/040313-255.1

**Direitos autorais / Publisher's copyright statement:**

©2013 by Edward H. Angle Society of Orthodontists. All rights reserved.

DIRETORIA DE TRATAMENTO DA INFORMAÇÃO

Cidade Universitária Zeferino Vaz Barão Geraldo

CEP 13083-970 – Campinas SP

Fone: (19) 3521-6493

<http://www.repositorio.unicamp.br>

## Influence of cone-beam computed tomography image artifacts on the determination of dental arch measurements

Thiago O. Gamba<sup>a</sup>; Matheus L. Oliveira<sup>b</sup>; Isadora L. Flores<sup>a</sup>; Adriana D. Cruz<sup>c</sup>; Solange M. Almeida<sup>d</sup>; Francisco Haiter-Neto<sup>e</sup>; Sérgio L.P.C. Lopes<sup>f</sup>

### ABSTRACT

**Objective:** To compare dental plaster model (DPM) and cone-beam computed tomography (CBCT) in the measurement of the dental arches, and investigate whether CBCT image artifacts compromise the reliability of such measurements.

**Materials and Methods:** Twenty patients were divided into two groups based on the presence or absence of metallic restorations in the posterior teeth. Both dental arches of the patients were scanned with the CBCT unit i-CAT, and DPMs were obtained. Two examiners obtained eight arch measurements on the CBCT images and DPMs and repeated this procedure 15 days later. The arch measurements of each patient group were compared separately by the Wilcoxon rank sum (Mann-Whitney *U*) test, with a significance level of 5% ( $\alpha = .05$ ). Intraclass correlation measured the level of intraobserver agreement.

**Results:** Patients with healthy teeth showed no significant difference between all DPM and CBCT arch measurements ( $P > .05$ ). Patients with metallic restoration showed significant difference between DPM and CBCT for the majority of the arch measurements ( $P > .05$ ). The two examiners showed excellent intraobserver agreement for both measuring methods with intraclass correlation coefficient higher than 0.95.

**Conclusion:** CBCT provided the same accuracy as DPM in the measurement of the dental arches, and was negatively influenced by the presence of image artifacts. (*Angle Orthod.* 2014;84:274–278.)

**KEY WORDS:** Anatomic models; Cone-beam computed tomography; Orthodontics

### INTRODUCTION

The assessment of tooth dimensions and dental arch relationships is of fundamental importance during orthodontic treatment planning. For this purpose, dental plaster model (DPM) obtained from traditional dental impression has been used extensively.<sup>1</sup> The manufacturing of plaster models requires large physical space for storage and involves great risk of damage, with loss of the patient's record. In case of multidisciplinary treatments, when the clinicians are located in different offices, DPMs have to be replicated and mailed, increasing the risk of distortions, labor costs, and time.<sup>2</sup> Hence, the search of a feasible alternative to the use of such models is of considerable interest.

In the late 1990s, cone-beam computed tomography (CBCT) was presented as a reliable image-acquisition method in the assessment of dental arches. CBCT acquires multiple planar projections by rotational scan and produces a volumetric dataset from which inter-relational images can be generated.<sup>3</sup> Studies have shown that CBCT-reconstructed study models are

<sup>a</sup> PhD Student, Department of Oral Diagnosis, Piracicaba Dental School, State University of Campinas, São Paulo, SP, Brazil.

<sup>b</sup> Assistant Professor, Department of Oral Diagnosis and Surgery, Araraquara Dental School, São Paulo State University, São Paulo, SP, Brazil.

<sup>c</sup> Adjunct Professor, Department of Specific Formation, Area of Radiology, Dental School of the Fluminense Federal University, Nova Friburgo, RJ, Brazil.

<sup>d</sup> Associate Professor, Department of Oral Diagnosis, Piracicaba Dental School, State University of Campinas, São Paulo, SP, Brazil.

<sup>e</sup> Professor, Department of Oral Diagnosis, Piracicaba Dental School, State University of Campinas, São Paulo, SP, Brazil.

<sup>f</sup> Assistant Professor, Department of Oral Diagnosis and Surgery, São José dos Campos Dental School, São Paulo State University, São Paulo, SP, Brazil.

Corresponding author: Dr Matheus Lima de Oliveira, Rua Humaitá, 1680, PO Box 331 Araraquara, SP, Brazil (e-mail: matheusoliveira@hotmail.com)

Accepted: June 2013. Submitted: April 2013.

Published Online: August 7, 2013

© 2014 by The EH Angle Education and Research Foundation, Inc.

comparable with plaster study models in the attainment of arch measurements, with a significant reduction of working time.<sup>4,5</sup>

A significant element that impairs CBCT image quality is image artifact. An artifact is any distortion in the image unrelated to the subject studied that may compromise the accuracy of the image. Because metallic structures have a high atomic number, they absorb mostly lower energy photons and produce dark bands and streaks in the image. This phenomenon is known as beam hardening and interferes with the identification and interpretation of dental structures.<sup>3,6</sup> Therefore, the aim of the present study was to compare DPM and CBCT in the measurement of the dental arches, and investigate whether CBCT image artifacts arising from metallic restorations compromise the reliability of such measurements.

## MATERIALS AND METHODS

Following approval by the local institutional research ethics committee (protocol 117/2009), 20 patients with a mean age of 22 years agreed to participate in the study and signed an informed consent form. They were under orthodontic treatment and referred for CBCT examination as a treatment indication. All patients presented a full set of erupted permanent dentition up to the second molars in both jaws and were divided into two groups: (1) the restored group, in which 10 patients presented only one metallic restoration in the posterior teeth per quadrant, and (2) the control group, in which 10 patients had healthy posterior teeth, with no metallic restoration. Exclusion criteria were dental implants and/or prosthesis.

DPMs were prepared from alginate impressions of all patients and filled with a homogeneous mixture of stone plaster following the manufacturer's instructions. In an endeavor to avoid distortions of the DPMs, they were removed from the alginate impression right after hardening.<sup>7</sup>

CBCT scans of both jaws were obtained using the i-CAT unit (Imaging Sciences, Hatfield, Penn, USA) at 120 kVp, 8 mA, exposure time of 26 seconds, and an extended field of view of 17 × 23 cm. The patients were positioned according to the manufacturer's guidelines, with the Frankfort plane perpendicular to the sagittal plane and parallel to the horizontal plane. A wooden spatula was placed between the jaws to avoid occlusal contact. Data were exported to DICOM file format and imported into the i-CAT vision software (Imaging Sciences). This public domain software enables the viewing of images by multiplanar reconstruction in different anatomic planes, namely: axial, coronal, and sagittal.

Two dentomaxillofacial radiologists with over 5 years of clinical experience were trained in a single session

with the purpose of presenting the image software, explaining the method of evaluation, and verifying the assimilation of the training. Then, they were asked to measure the following distances on the DPMs and axial slices of CBCT images: upper and lower intercanine distances (UICD, LICD), measurement between the tip of the right and left canines of the same jaw; upper and lower intermolar distances (UIMD, LIMD), measurement between the mesiobuccal cusp of the right and left first molars of the same jaw; upper and lower required spaces (URS, LRS), sum of the mesiodistal distances of the teeth between the left and right first molars of the same jaw; and upper and lower arch perimeters (UAP, LAP), curved distance between the mesial surface of the left and right first molars of the same jaw (Figures 1 and 2). Because all distances were based on a precise selection of predefined points, the examiners were allowed to scroll up and down the CBCT axial images to pick the slice that provided better visualization of each point.

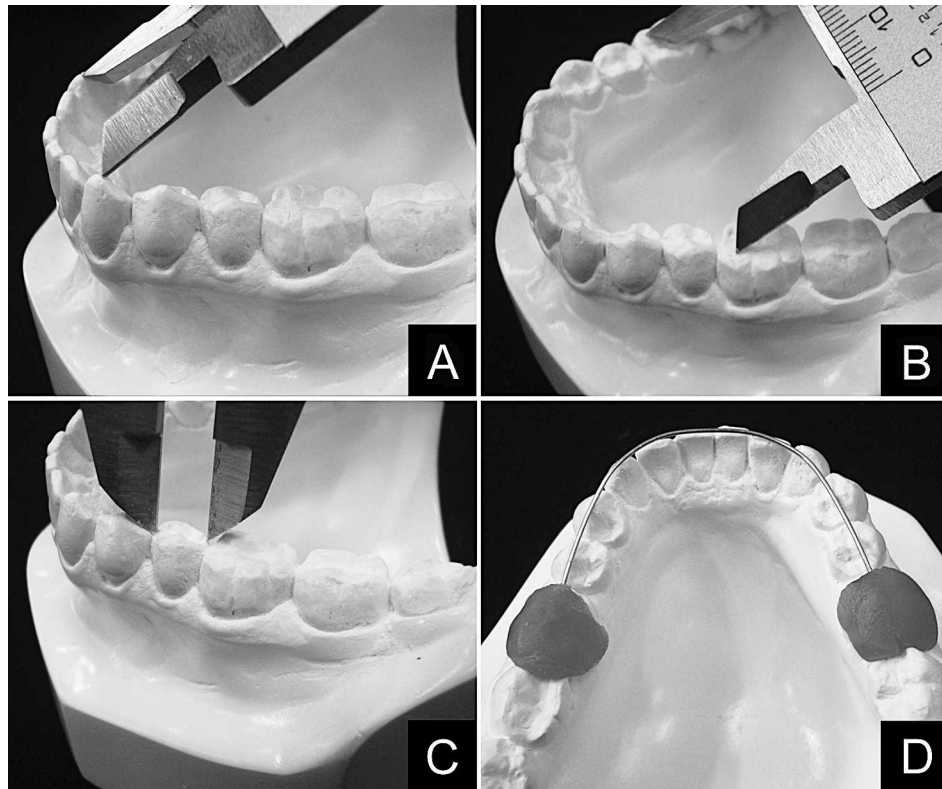
A digital caliper was used to perform the linear measurements on the DPMs. The AP, which is a curved measurement, was obtained by measuring an orthodontic wire after placing it on the region of interest (Figure 1). Under subdued room lighting, the CBCT images were displayed on a 17-inch LCD monitor (Samsung, Seoul, South Korea), and the measurements were performed using the distance measurement tool provided by the software (Figure 2). Fifteen days later, in order to test the intraobserver reproducibility, the examiners repeated all arch measurements previously mentioned.

After exploratory analysis of the data, the arch measurements from DPM and CBCT of each patient group were compared separately by the Wilcoxon rank sum (Mann-Whitney *U*) test. Intraclass correlation measured the level of intraobserver agreement. All statistical analysis was carried out using the Stata Statistics/Data Analysis version 11.0 software (Stata-Corp, College Station, Tex) with a significance level of 5% ( $\alpha = .05$ ) and power of 80%.

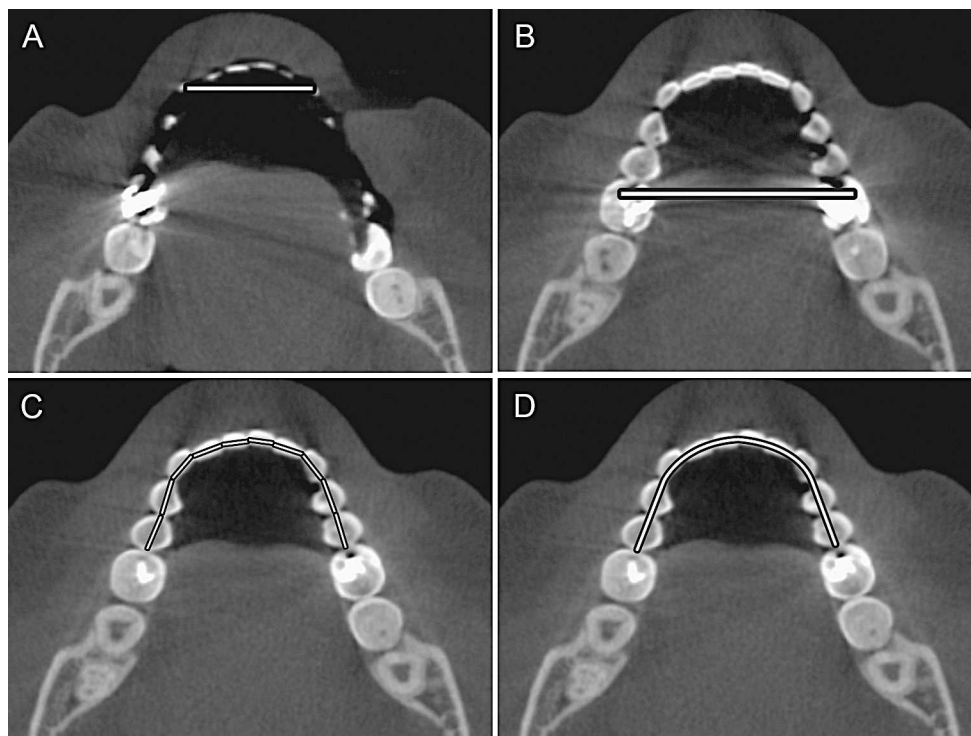
## RESULTS

The age of the patients varied from 19 to 24 years with a mean of 22 ( $\pm 1.76$ ) and a median of 22.5 years. All patients presented healthy anterior teeth. The group of patients with metallic restoration presented only one restoration per quadrant in either the first or second molars such that 36 restorations were in the occlusal surface and four involved two surfaces (mesial-occlusal or occlusal-distal).

In the group of patients with healthy teeth, mean values of CBCT arch measurements were mostly higher than those obtained from DPM. However, no



**Figure 1.** Mandibular measurements on a dental plaster model. (A) Intercanine distance. (B) Intermolar distance. (C) Second premolar mesiodistal distance, as part of the required space. (D) Orthodontic wire representing the arch perimeter.



**Figure 2.** Mandibular measurements on CBCT axial images. (A) Intercanine distance. (B) Intermolar distance. (C) Required space. (D) Dental arch perimeter.

**Table 1.** Mean Values of Arch Measurements (in mm) Obtained From Dental Plaster Model (DPM) and Cone-beam Computed Tomography (CBCT) of Patients With Healthy Teeth<sup>a</sup>

Measurement <sup>a</sup>	Healthy Teeth Patients		U	P Value <sup>b</sup>
	DPM (±SD)	CBCT (±SD)		
UICD	33.21 (2.58)	32.72 (2.51)	0.476	>.05
LICD	25.44 (2.88)	25.79 (2.46)	-0.526	>.05
UIMD	47.43 (2.85)	47.25 (3.14)	0.315	>.05
LIMD	44.65 (3.61)	44.32 (3.74)	0.210	>.05
URS	88.75 (5.90)	88.93 (5.88)	-0.105	>.05
LRS	81.69 (6.44)	81.80 (7.01)	0.000	>.05
UAP	69.68 (11.19)	72.34 (8.12)	-0.211	>.05
LAP	62.53 (7.04)	62.75 (7.11)	-0.211	>.05

<sup>a</sup> UICD and LICD indicate upper and lower intercanine distances; UIMD and LIMD, upper and lower intermolar distances; URS and LRS, upper and lower required space; and UAP and LAP, upper and lower arch perimeters.

<sup>b</sup>  $P > .05$  indicates that both the DPM and CBCT arch measurements are equal by the Wilcoxon rank sum (Mann-Whitney *U*) test.

significant difference was observed between all DPM and CBCT arch measurements ( $P > .05$ ) (Table 1).

Table 2 shows mean values of arch measurements of patients with metallic restoration in the posterior teeth. CBCT arch measurements were higher than DPM, and all of them had low standard deviation. Significant difference was observed between DPM and CBCT for UICD, LICD, UIMD, LIMD, UAP, and LAP ( $P > .05$ ).

The two examiners showed excellent intraobserver agreement for both measuring methods—DPM and CBCT—with intraclass correlation coefficient higher than 0.95 (Table 3).

**Table 2.** Mean Values of Arch Measurements (in mm) Obtained From Dental Plaster Model (DPM) and Cone-beam Computed Tomography (CBCT) of Patients With Metallic Restoration<sup>a</sup>

Measurement <sup>a</sup>	Restoration		U	P Value <sup>b</sup>
	DPM (±SD)	CBCT (±SD)		
UICD	32.68 (2.01)	34.74 (2.36)	-2.696	<.05*
LICD	25.36 (1.81)	27.49 (1.49)	-2.978	<.05*
UIMD	48.31 (2.41)	50.81 (2.66)	-2.490	<.05*
LIMD	43.26 (1.96)	46.47 (2.31)	-3.393	<.05*
URS	88.05 (4.60)	90.38 (5.12)	-1.508	>.05
LRS	78.80 (4.38)	82.17 (4.27)	-1.885	>.05
UAP	70.14 (2.94)	72.81 (3.74)	-2.350	<.05*
LAP	61.31 (2.37)	63.97 (2.74)	-2.892	<.05*

<sup>a</sup> UICD and LICD indicate upper and lower intercanine distances; UIMD and LIMD, upper and lower intermolar distances; URS and LRS, upper and lower required space; and UAP and LAP, upper and lower arch perimeters.

<sup>b</sup>  $P > .05$  indicates that both the DPM and CBCT arch measurements are equal by the Wilcoxon rank sum (Mann-Whitney *U*) test.

\* Statistical difference.

**Table 3.** Intraclass Correlation Coefficient of the Examiners on the Two Measuring Methods<sup>a</sup>

Examiner	DPM	CBCT
1	0.967	0.983
2	0.954	0.991

<sup>a</sup> DPM indicates dental plaster model; CBCT, cone-beam computed tomography.

**DISCUSSION**

The use of CBCT has increased with the possibility of determining measurements of the dental arches on three-dimensional images.<sup>8,9</sup> In orthodontics, DPM has preceded CBCT and played an essential role in treatment planning for decades, though it involves some drawbacks as previously described.<sup>1,2</sup> Many orthodontists have incorporated digital orthodontic diagnosis in their clinical practice by using computer software systems.<sup>10</sup> Despite the high resolution and great image quality presented by current digital images, it is important to check if they allow better accuracy and precision on different tasks.<sup>11</sup> Several studies have evaluated the ability of CBCT in measuring the dental arch and surrounding structures.<sup>1,2,4,5,8,9</sup> Mullen et al.<sup>5</sup> and Luu et al.<sup>12</sup> demonstrated that CBCT is as accurate as DPM in the attainment of measurements, which is in agreement with the present study. Arch measurements obtained from patients with healthy teeth did not differ between DPM and CBCT. This suggests, in part, that the DPMs from alginate impressions used in our study were a faithful representation of the dental arches.<sup>7</sup> Luu et al.<sup>12</sup> and Lighthart et al.<sup>13</sup> revealed that CBCT-reconstructed virtual models are reliable for adequate orthodontic treatment planning. Additionally, Wiranto et al.<sup>2</sup> and Gracco et al.<sup>4</sup> stated that virtual models are an effective alternative to DPM in orthodontic practice, with the advantage of significant time reduction.

The present study also compared arch measurements obtained from DPM and CBCT of patients who presented a metallic restoration in the posterior teeth. Considering that high-density materials may produce image artifacts, special attention should be paid to the evaluation of the dental arches. Our results showed that the majority of the CBCT arch measurements were negatively influenced by the presence of metallic restoration, with a significant increase of the mean values. In this case, streaks arising from such restorations could have induced misleading measurements.<sup>6</sup> The URS and LRS did not seem to be influenced by CBCT image artifacts. It can be possibly explained by the fact that the measurement of required space involved several nonrestored teeth, ie, anterior teeth, which may have minimized some errors induced by restored teeth. Also, the high standard deviation

observed on URS and LRS reflected the challenge of obtaining multipoint measurements. Any change from a true dimension may favor false interpretation and constitute potential risks of misdiagnosis.<sup>14,15</sup>

Image artifacts resulting from metallic filling material can also interfere with measurements,<sup>14</sup> but none of our patients presented such a condition. An important and relevant finding, recently presented by Wiranto et al.,<sup>2</sup> is that CBCT scanning of alginate impressions is valid, reliable, and reproducible. In that case, there would not be direct interactions of the x-rays with metallic restorations, nor image degradation by artifacts. Murphy et al.<sup>16</sup> stated that even though some studies have reported problems caused by image artifact, streak artifact is not considered to be a major problem in forensic dental identification.

Overall, mean values of CBCT arch measurements were higher than those obtained from DPM, which is in agreement with Mullen et al.<sup>5</sup> Such an increase was greater in patients with metallic restorations than with patients who had healthy teeth. This reinforces the possible interference caused by image artifacts. Moreover, all mean values of required space were higher than arch perimeter, which demonstrates a sample of patients with crowding, and justifies their orthodontic treatment. The excellent intraobserver reproducibility obtained in this study revealed that all observers were reliable with regard to determining arch dimensions, and both measuring methods—DPM and CBCT—allowed excellent precision. Sheikhi et al.<sup>17</sup> demonstrated that the accuracy of measurements in CBCT machine varies when the position of the skull deviates from ideal. However, this shall not be considered in the present study, since all patients were positioned the same way, as explained in the methodology section. Because the involved tooth and the extension of all metallic restorations were very similar to each other, this study did not statistically evaluate the effect of anatomic location of metallic restoration on CBCT images. Differences in tissue thickness and cone-beam geometry at different anatomic sites may vary the amount and pattern of scattered radiation and beam hardening.<sup>3</sup>

## CONCLUSIONS

- CBCT provided the same accuracy as DPM in the measurement of healthy dental arches.
- CBCT image artifacts arising from metallic restorations compromised the reliability of the arch measurements, except for upper and lower required spaces.
- Further studies in a larger sample with patient groups based on the restored tooth are required to better investigate the location-dependent effect of metallic restoration on CBCT images.

## REFERENCES

1. Redlich M, Weinstock T, Abed Y, Schneor R, Holdstein Y, Fischer A. A new system for scanning, measuring and analyzing dental casts based on a 3D holographic sensor. *Orthod Craniofac Res.* 2008;11:90–95.
2. Wiranto MG, Engelbrecht WP, Tutein Nolthenius HE, van der Meer WJ, Ren Y. Validity, reliability, and reproducibility of linear measurements on digital models obtained from intraoral and cone-beam computed tomography scans of alginate impressions. *Am J Orthod Dentofacial Orthop.* 2013;143:140–147.
3. Oliveira ML, Tosoni GM, Lindsey DH, Mendoza K, Tetradis S, Mallya SM. Influence of anatomical location on CT numbers in cone beam computed tomography. *Oral Surg Oral Med Oral Pathol Oral Radiol.* 2013;115:558–564.
4. Gracco A, Buranello M, Cozzani M, Siciliani G. Digital and plaster models: a comparison of measurements and times. *Prog Orthod.* 2007;8:252–259.
5. Mullen SR, Martin CA, Ngan P, Gladwin M. Accuracy of space analysis with emodels and plaster models. *Am J Orthod Dentofacial Orthop.* 2007;132:346–352.
6. Schulze R, Heil U, Gross D, et al. Artifacts in CBCT: a review. *Dentomaxillofac Radiol.* 2011;40:265–273.
7. Marquezan M, Jurach EM, Guimarães VD, Valentim RG, Nojima LI, Nojima Mda C. Does the contact time of alginate with plaster cast influence its properties? *Braz Oral Res.* 2012;26:197–201.
8. Cevidanes LH, Styner MA, Proffit WR. Image analysis and superimposition of 3-dimensional cone-beam computed tomography models. *Am J Orthod Dentofacial Orthop.* 2006;129:611–618.
9. Wang Y, He S, Yu L, Li J, Chen S. Accuracy of volumetric measurement of teeth in vivo based on cone beam computer tomography. *Orthod Craniofac Res.* 2011;14:206–212.
10. Makdissi J. Cone beam CT in orthodontics: the current picture [in English, French]. *Int Orthod.* 2013;11:1–20.
11. Oliveira ML, Ambrosano GM, Almeida SM, Haiter-Neto F, Tosoni GM. Efficacy of several digital radiographic imaging systems for laboratory determination of endodontic file length. *Int Endod J.* 2011;44:469–473.
12. Luu NS, Nikolcheva LG, Retrouvey JM, et al. Linear measurements using virtual study models. *Angle Orthod.* 2012;82:1098–1106.
13. Lighthead KG, English JD, Kau CH, et al. Surface analysis of study models generated from OrthoCAD and cone-beam computed tomography imaging. *Am J Orthod Dentofacial Orthop.* 2012;141:686–693.
14. Decurcio DA, Bueno MR, de Alencar AH, Porto OC, Azevedo BC, Estrela C. Effect of root canal filling materials on dimensions of cone-beam computed tomography images. *J Appl Oral Sci.* 2012;20:260–267.
15. Schulze RK, Berndt D, d'Hoedt B. On cone-beam computed tomography artifacts induced by titanium implants. *Clin Oral Implants Res.* 2010;21:100–107.
16. Murphy M, Drage N, Carabott R, Adams C. Accuracy and reliability of cone beam computed tomography of the jaws for comparative forensic identification: a preliminary study. *J Forensic Sci.* 2012;57:964–968.
17. Sheikhi M, Ghorbanizadeh S, Abdinian M, Goroohi H, Badrian H. Accuracy of linear measurements of galleos cone beam computed tomography in normal and different head positions. *Int J Dent.* 2012;2012:214954.